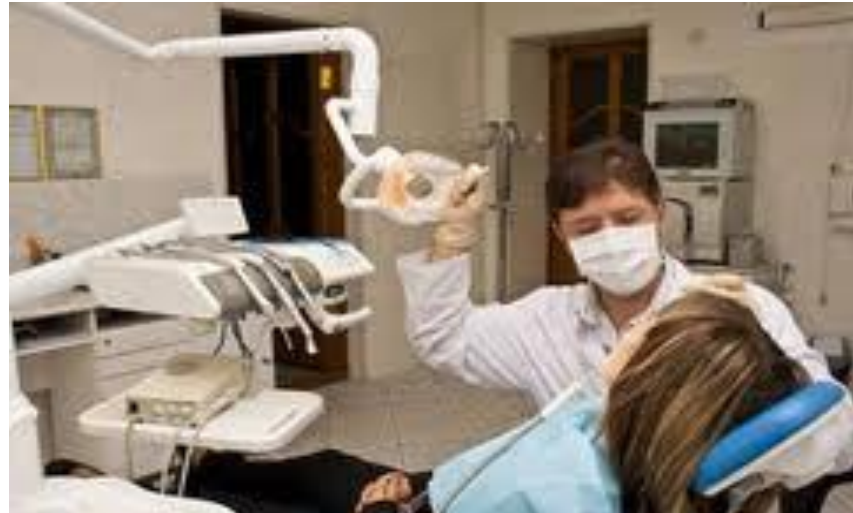

**Paraclinical examination.
Radiographic examination (OPG,
CT), laboratory, bacteriological
examination**




RADIOGRAPHS

- Appropriate radiographs form an essential part of a periodontal assessment and the patient's clinical record, but remember like many indicators of disease, they only provide retrospective evidence of the disease process.

When to take radiographs?


- Radiographs can be used to aid diagnosis and help determine the likely prognosis of specific teeth when taken together with a comprehensive clinical examination and patient history


- By permitting assessment of the morphology of the affected teeth and the pattern and degree of alveolar bone loss they can also be invaluable for treatment planning and in monitoring the long-term stability of periodontal health. By providing information on other pathologies, such as periapical pathology, pulpal/furcation involvements and caries, radiographs also provide a guide to the overall prognosis of teeth.

- 
- This guide does not aim to dictate the choice of radiographs as each patient will have their own unique clinical presentation but care should be taken to ensure that each exposure is clinically justified, of suitable quality to be useful and provide clear benefit to the patient.

Initial presentation

- The number and type of radiographs required will depend on your findings during the clinical examination. You may choose to take radiographs as part of your special investigations on completion of the BPE. Although if a detailed periodontal chart is required you may decide to wait and use this additional information to help decide which views would be most appropriate.

- 
- Radiographs can also be useful to track changes in bone levels over time, for example in areas of furcation involvement or in patients where there is uncertainty as to the aggressiveness of the disease process.

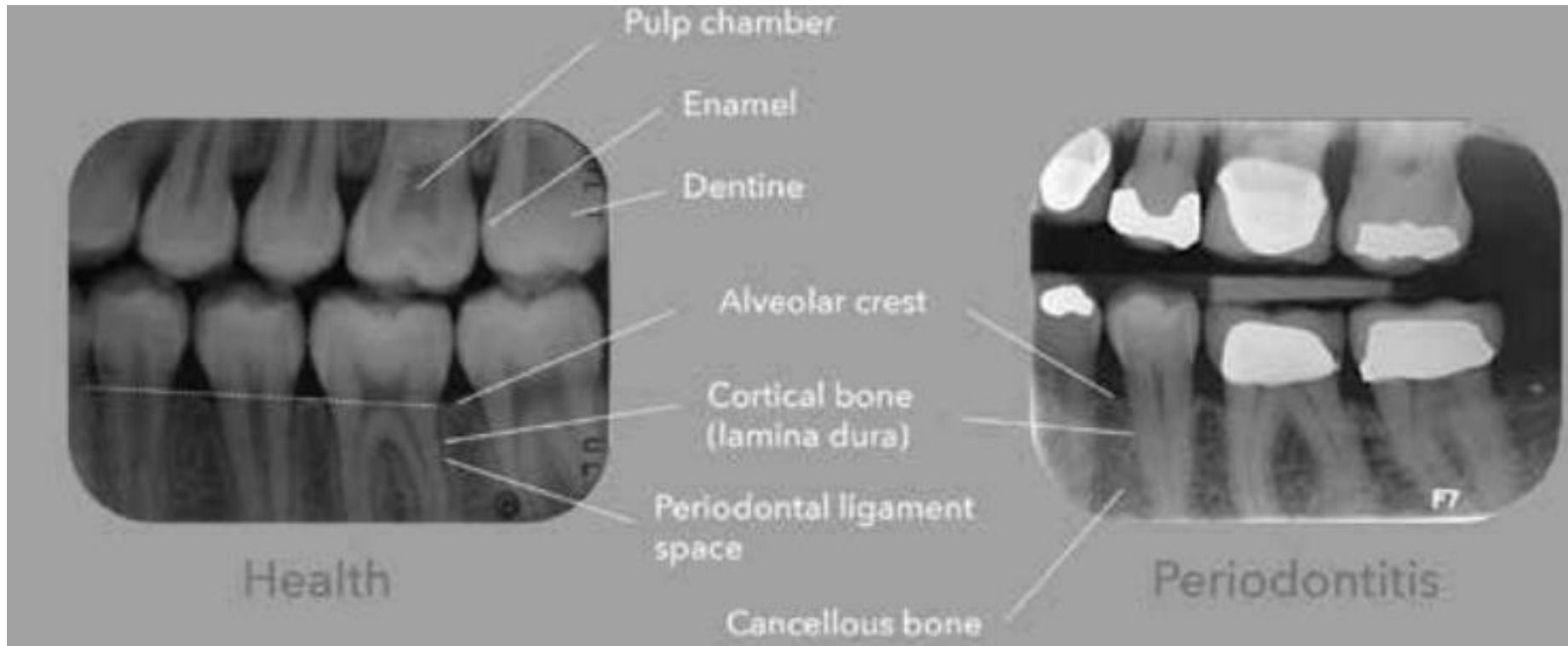
- 
- Clinical need should determine the frequency of repeat radiographs. Bone loss is slow to become apparent on sequential radiographs

Which radiographs?

Horizontal bitewings

- Bitewing radiographs are likely to be taken routinely for assessing caries. They may also give early warning of localised bone loss, the presence of poorly contoured restorations and subgingival calculus. The normal positioning of the film should automatically ensure a non-distorted view of bone levels in relation to the cemento-enamel junction (CEJ).

Radiographic features of the periodontium on a horizontal bitewing film. In health the alveolar crest is roughly horizontal, about 2-3mm apical to and parallel to a line joining adjacent CEJs.




Vertical bitewings

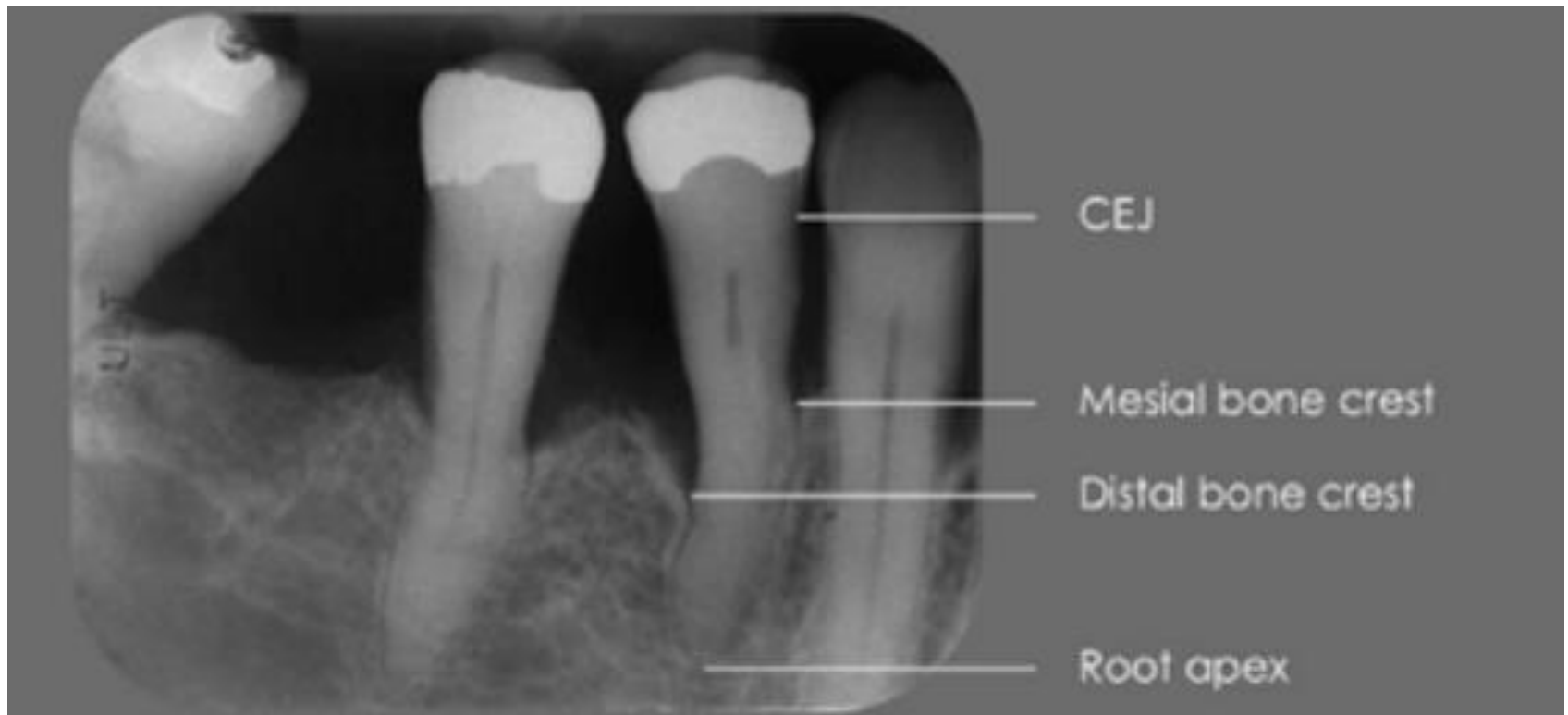
- Correctly positioned, this type of radiograph provides a non-distorted view of bone levels in relation to CEJs, in opposing arches. Vertical bitewings can provide better visualisation of the bone level than horizontal bitewings. However, they can be difficult to position accurately in patients especially those with more shallow palates. Selected periapicals may be more appropriate where assessment of apical status could be important.

Periapicals

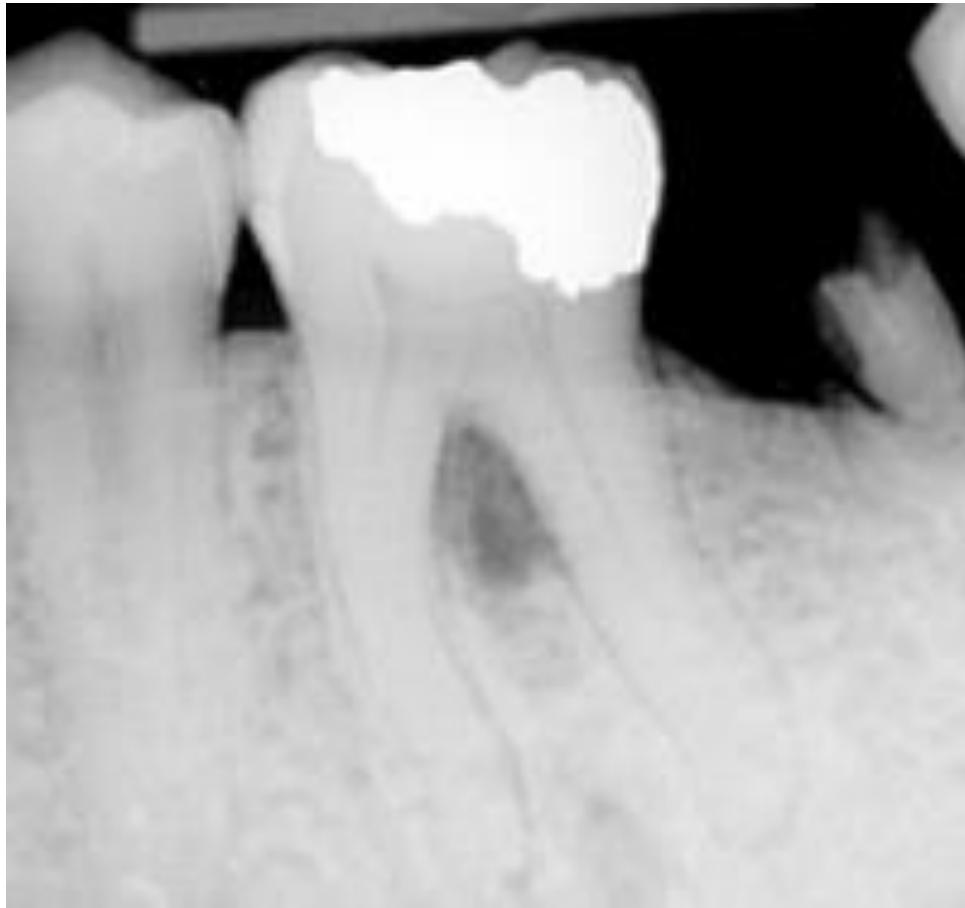
- The gold standard radiograph for periodontal assessment is a periapical radiograph taken using a long-cone paralleling technique. Correctly positioning this radiograph will give an accurate, non-distorted two dimensional picture of bone levels in relation to both CEJs and total root length. This technique involves the use of a beam aiming device which helps achieve better and more consistent results.

- 
- Visualising root anatomy in its entirety can be very useful in assessing bone levels in relation to total root length in:
 - Assessing prognosis
 - Helping to assess furcation involvements
 - Identifying possible endodontic complications

Periapical radiograph showing both horizontal and angular bony defects.



Perio-endo lesion

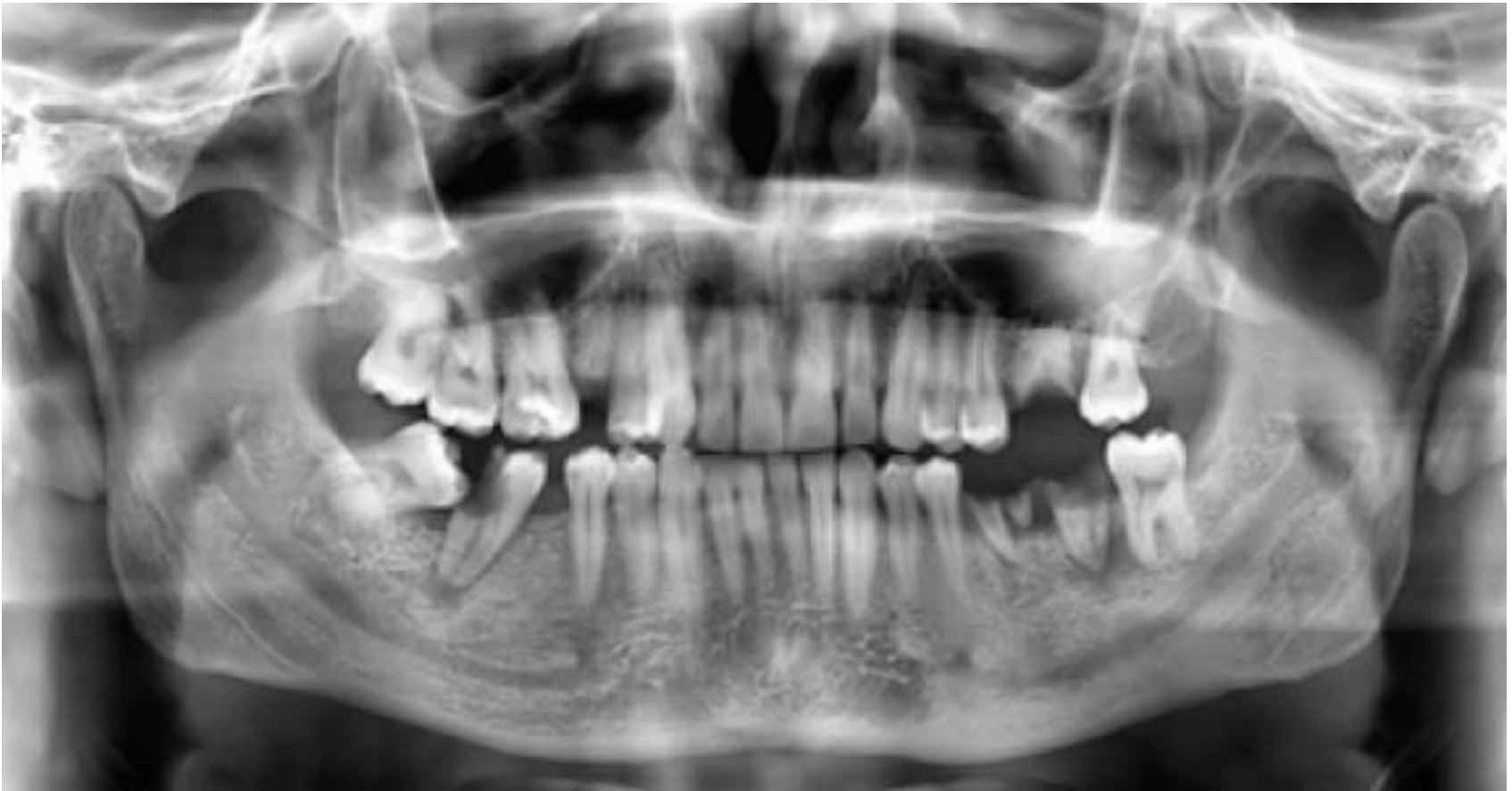



Dental panoramic tomographs (DPTs)/OPG


- There is no case for routine screening with panoramic films. The yield of information is low for screening given the radiation dosage. In complex cases where there are a variety of dental concerns a DPT could be considered.

A DPT can be useful for bone level assessment in complex cases where there are a variety of dental concerns



Periapical vs panoramic radiographs


- The choice of panoramic vs. intra-oral periapical radiographs may depend on a range of factors including preference and availability. In general, full mouth periapical radiographs using a paralleling technique, give more accurate and detailed assessment of periodontal bony defects.

- 
- In contrast, a good quality panoramic radiograph is quicker, less uncomfortable, and may provide useful assessment of bone levels and other pathologies. Panoramic radiographs might need to be supplemented with periapical views especially in the anterior sextants due to the likelihood of image distortion in these regions

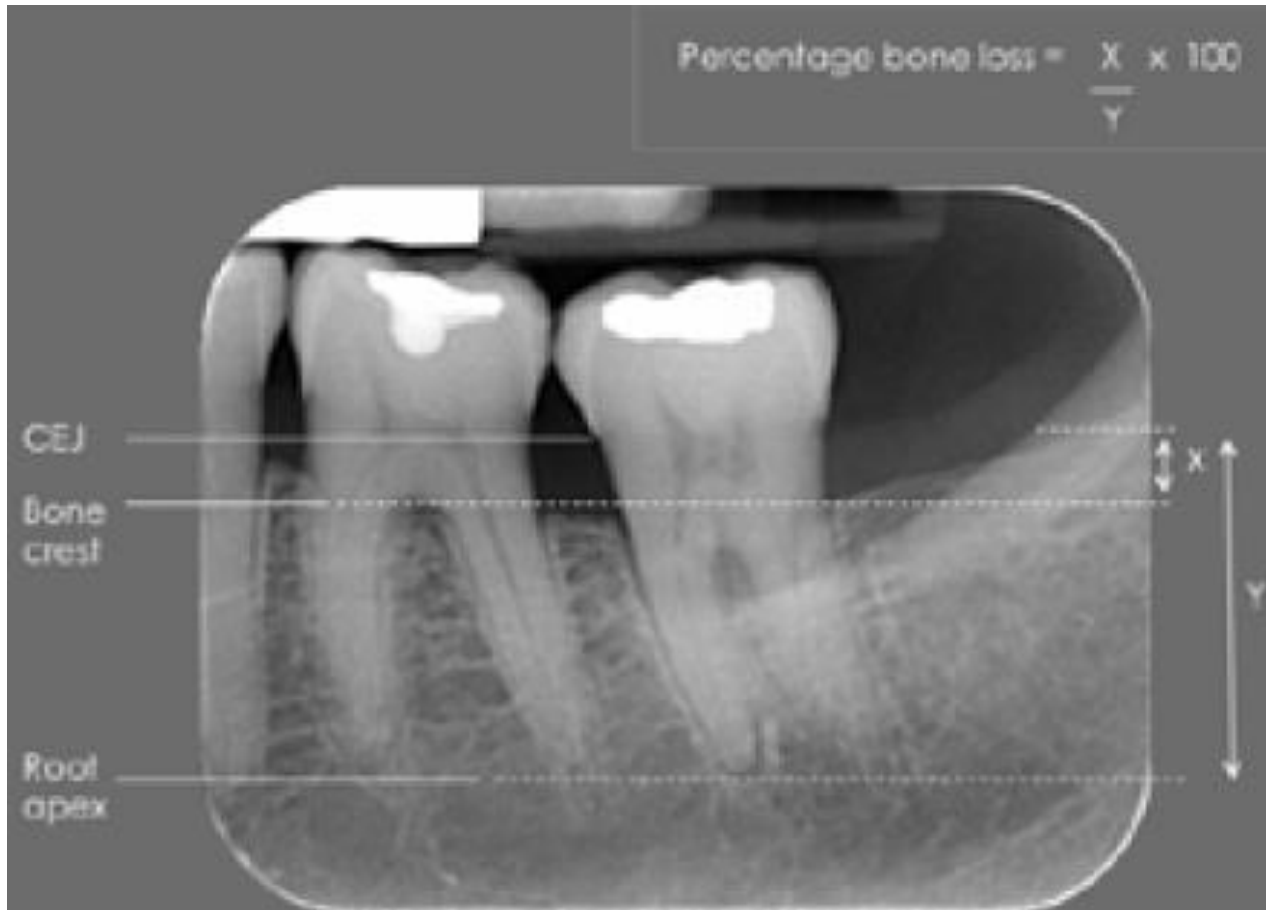


Radiographic periodontal assessment

- Medico-legally it is important that you report your radiographic findings in the clinical notes and this should include an assessment of the image quality.

- 
- Periodontally, radiographs should be assessed for:
 - Degree of bone loss: if the apex is visible then bone loss should be measured and reported as a percentage
 - Pattern or type of bone loss: e.g. horizontal bone loss or angular (vertical) defects
 - Presence of furcation defects
 - Presence of subgingival calculus
 - Other features: e.g. perio-endo lesions; widened periodontal ligament spaces; abnormal root length or root morphology; overhanging restorations


Calculating percentage bone loss



- 
- Radiographs can also be helpful for assessing expectations of treatment. For example:
 - If there are angular defects more than 3mm deep you should not expect dramatic pocket reductions with simple non-surgical therapy
 - Multiple angular defects and furcation involvement suggest a complex treatment need and consideration for referral.

Use of cone beam computed tomography in periodontology (CB CT)

- However, in the case of bone destruction, radiographs are valuable diagnostic tools as an adjunct to the clinical examination. Two dimensional periapical and panoramic radiographs are routinely used for diagnosing periodontal bone levels. In two dimensional imaging, evaluation of bone craters, lamina dura and periodontal bone level is limited by projection geometry and superpositions of adjacent anatomical structures.

- 
- Those limitations of 2D radiographs can be eliminated by three-dimensional imaging techniques such as computed tomography. Cone beam computed tomography (CBCT) generates 3D volumetric images and is also commonly used in dentistry. All CBCT units provide axial, coronal and sagittal multi-planar reconstructed images without magnification.


- 
- Also, panoramic images without distortion and magnification can be generated with curved planar reformation. CBCT displays 3D images that are necessary for the diagnosis of intra bony defects, furcation involvements and buccal/lingual bone destructions. CBCT applications provide obvious benefits in periodontics, however; it should be used only in correct indications considering the necessity and the potential hazards of the examination.

Table 1

Comparison of cone beam computed tomography and medical computed tomography are listed in the table

CBCT	Medical CT
Single rotation	Multiple rotations
Lower radiation dose	Higher radiation dose
Isotropic voxels	Anisotropic voxels
Lower cost	Higher cost
Smaller space requirement	Larger devices
Better spatial resolution	Better contrast resolution
Deficiency to display soft tissues	Clear evaluation of soft tissues
Higher scatter radiation	Lower scatter radiation

CT: computed tomography; CBCT: Cone beam computed tomography.

Table 2

The table shows the features of cone beam computed tomography and conventional radiographs

CBCT	Conventional radiography
3D imaging	2D imaging
Cross-sectional and volumetric images	Superpositions
Elimination of image deformity	Distortion and magnification
Higher radiation dose	Lower radiation dose
Higher cost	Lower cost
Larger devices	Smaller space requirement

CBCT: Cone beam computed tomography.

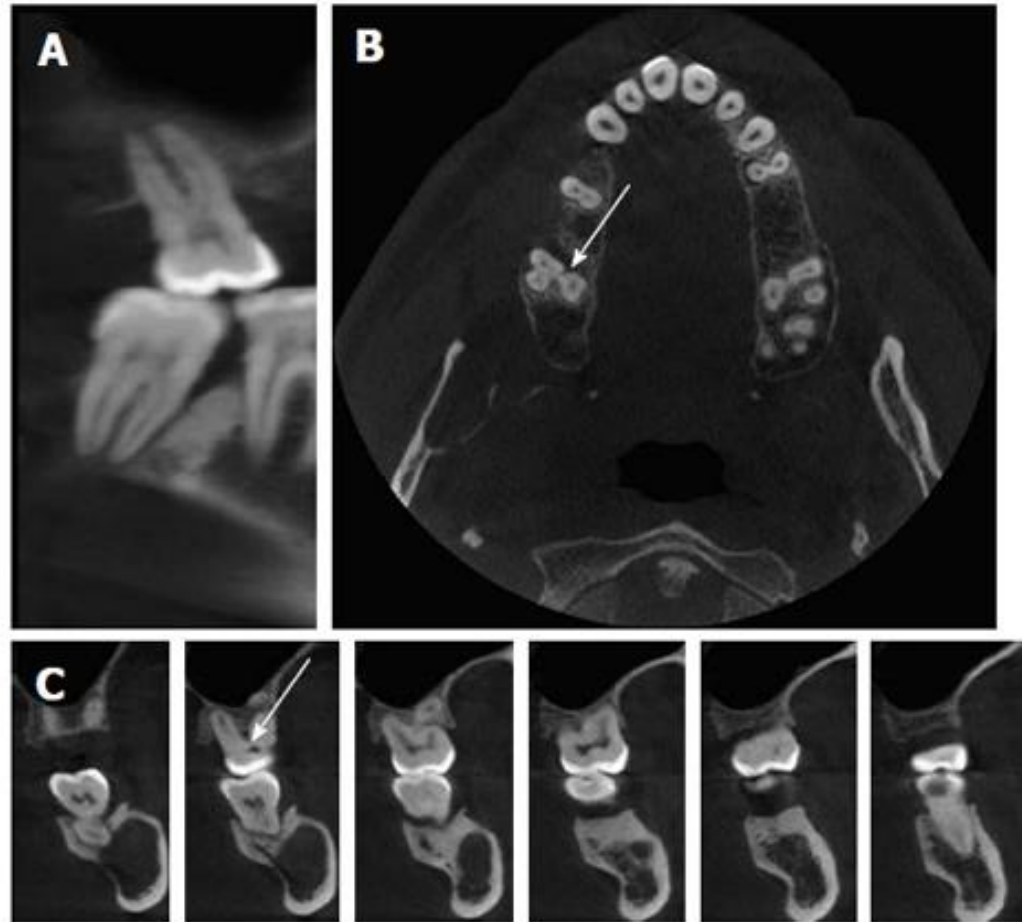


Figure 7


Furcation involvement can not be observed in the panoramic-like section (A) whereas it can be evaluated in the axial (B) and cross-sectional (C) cone beam computed tomography image (arrows).

Bacterial examination of periodontal disease

- Bacterial examination methods that detect the presence of bacteria, but not the amount, are termed qualitative examinations


https://www.researchgate.net/publication/21923751_Microbiological_Diagnosis_for_Periodontal_Diseases

Method	Principle	Advantages	Disadvantages	Comments
Culturing	Culturing of oral specimens on a medium	Detection of viable bacteria. Antibiotic sensitivity.	Unculturable bacteria. Requires bacteriology skill.	Important for antibiotic selection.
Enzymatic	Measurement of enzymatic activities produced by oral bacteria	Rapid and low-cost method.	Cannot identify bacterial species.	Commercial kits are available.
Immunological	Detection of specific bacteria using antibodies	Available for specific bacteria.	Cannot discriminate between living and dead cells.	Requires special techniques.
Conventional PCR	Detection of bacteria by DNA amplification	High sensitivity, qualitative analysis.	Same as above. Quantitative detection is not available.	Requires a thermal cycler.
Real-time PCR	Detection of bacteria by DNA amplification	High sensitivity, quantification.	Cannot discriminate between living and dead cells.	Requires a thermal cycler.
Loop-mediated isothermal amplification (LAMP)	Isothermal DNA amplification	High sensitivity, isothermal amplification, visual detection.	Same as conventional PCR.	Developed by Eiken Chemical Co., Ltd.



Microbiological examinations for the purpose of antibiotic selection

- Periodontal tissue debridement and root planing are the initial therapeutic approaches for periodontal disease. However, mechanical periodontal debridement can have poor therapeutic efficacy in some cases, owing to the invasion of periodontopathic bacteria into the periodontal tissue.

- 
- In such cases, antibiotic therapy is often effective (Slots et al., 2004). Antibiotics can be chosen based on the specific pathogens identified by microbiological examination. *Porphyromonas gingivalis*, *A. actinomycetemcomitans*, *T. forsythia*, and *T. denticola* are common target bacteria. In next table it's shows the recommended antibiotics according to bacterial type.

	Red complex: <i>Porphyromonas gingivalis</i> , <i>Tannerella forsythia</i> , <i>Treponema denticola</i>	<i>Aggregatibacter</i> <i>actinomycetemcomitans</i>	Orange complex: <i>Prevotella intermedia</i> , <i>Fusobacterium nucleatum</i>
Pathogenicity	High	High	Moderately high
Amoxicillin	-	+	-
Clindamycin	+	-	+
Doxycycline	+	+	+
Minocycline	+	+	+
Azithromycin	-	+	-
Ciprofloxacin	-	+	-
Metronidazole	+	-	+
Amoxicillin + Metronidazole	+		+

Table 3. Periodontopathic bacteria and recommended antibiotics (Shaddox & Waller, 2009).

- 
- <https://pdfs.semanticscholar.org/8bc5/33898340238d27bece3a87e1cdb4ad39d934.pdf>