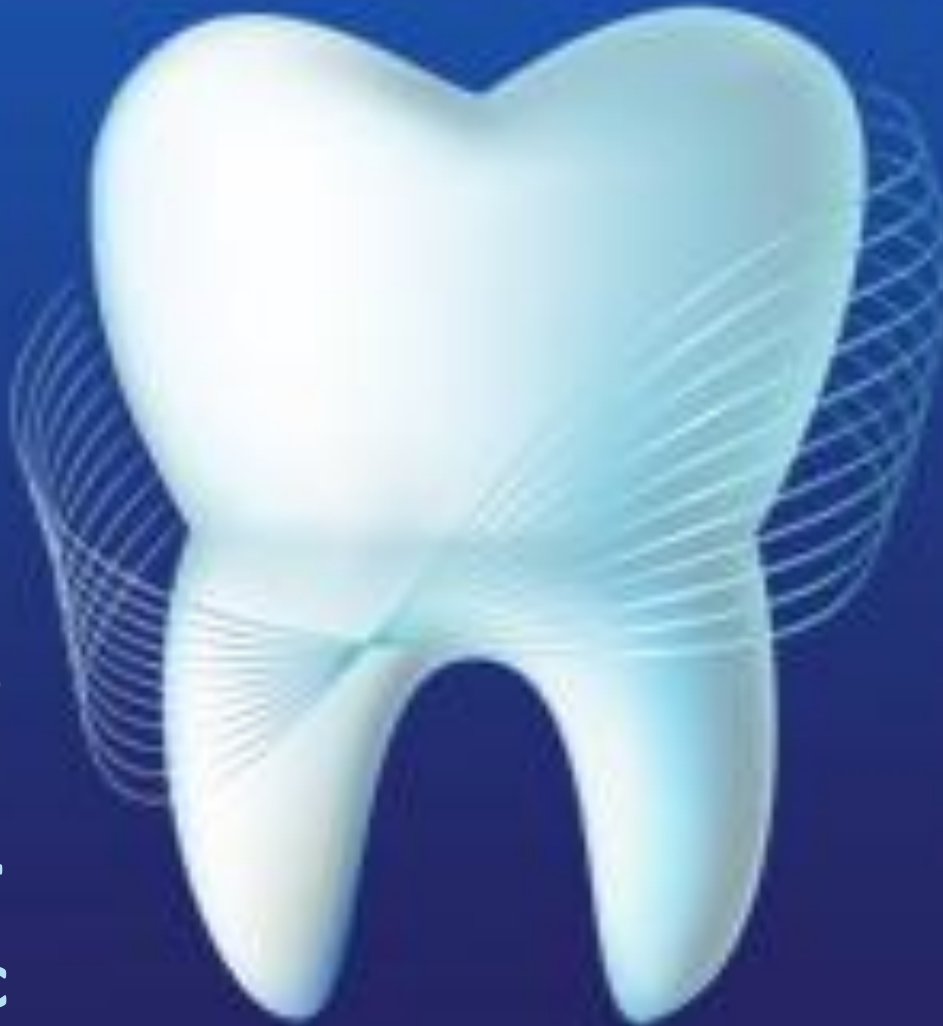
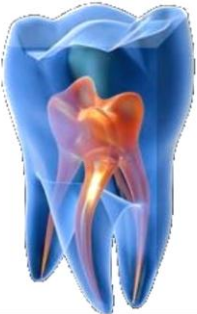
CANDIDIASIS OF ORAL MUCOSA. CLINICAL PICTURES. TREATMENT. PROPHYLAXIS



Lecture № 4
5 Year
10 Semester
V.Nicolaiciuc



Introduction

This is true for fungi that are saprophytes.

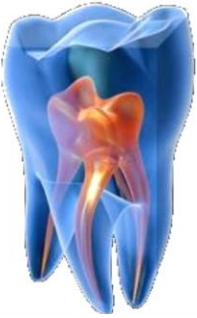As well as for fungi that are obligatory parasites and appropriately considered true pathogens.

Fungi are a part of the world plants. Approximately 100.000 different types of fungi have predominantly ecologic importance and useful functions (for example, in fermentation and purification). Only about 50 types of fungi cause disease in humans.

This can cause superficial infection (dermatomycosis), deep mycosis and systemic mycosis. Human pathogens, medically important types of fungi are Candida group.

In etiology is more important the change and decrease in the level of tolerance. As long as the living organism can tolerate the fungi on its surface (mucous membrane) there is no outbreak of disease. The level of tolerance is decided by immunologic defense of the host.

- ☐ Condition induced by medication, such as antibiotic therapy.
- ☐ Immunosuppressive agents.
- ☐ Cytostatics.
- ☐ Corticosteroids.
- ☐ HIV infection (AIDS).
- ☐ Immune defects (especially in cell-mediated immunity).



Based opportunistic Candida infection:

- ☐ Aspergilli;
- ☐ Cryptococci;
- ☐ Histoplasmosis.
- ☐ They are significant in HIV infection.
- ☐ Candidiasis, that is, findings in the mucous membrane and skin in the presence of yeast under various conditions of the host defenses (saprophyte, facultative pathogens, opportunistic infection).

Candida albicans is among the group members, with more than 120 types. It is the most frequently found and the most pathogenic aerobic fungus in humans under certain conditions. As harmless saprophytes of the oral cavity (latent thrush).

A Fungal disease (mycosis) will depend mostly on the availability of the fungus and not as much on local factors, but on general factors of the host organism.

Yeast infections were recognized centuries ago as indicators of an underlying serious illness such as:

- ☐ Malignant tumors;
- ☐ Leukemias;
- ☐ Chronic infectious diseases;
- ☐ Diabetes mellitus.



The fungal spread that develops rapidly (thrush) covers the bacteria flora that is just developing in scattered areas of the mouth. After a short time, the fungus yields to the normal local bacteria of the oral cavity in the healthy newborn.

During antibacterial chemotherapy, an ecologic gap develops to the advantage of the fungi, because the normal flora is suppressed to the advantage of *Candida* in the oral cavity.

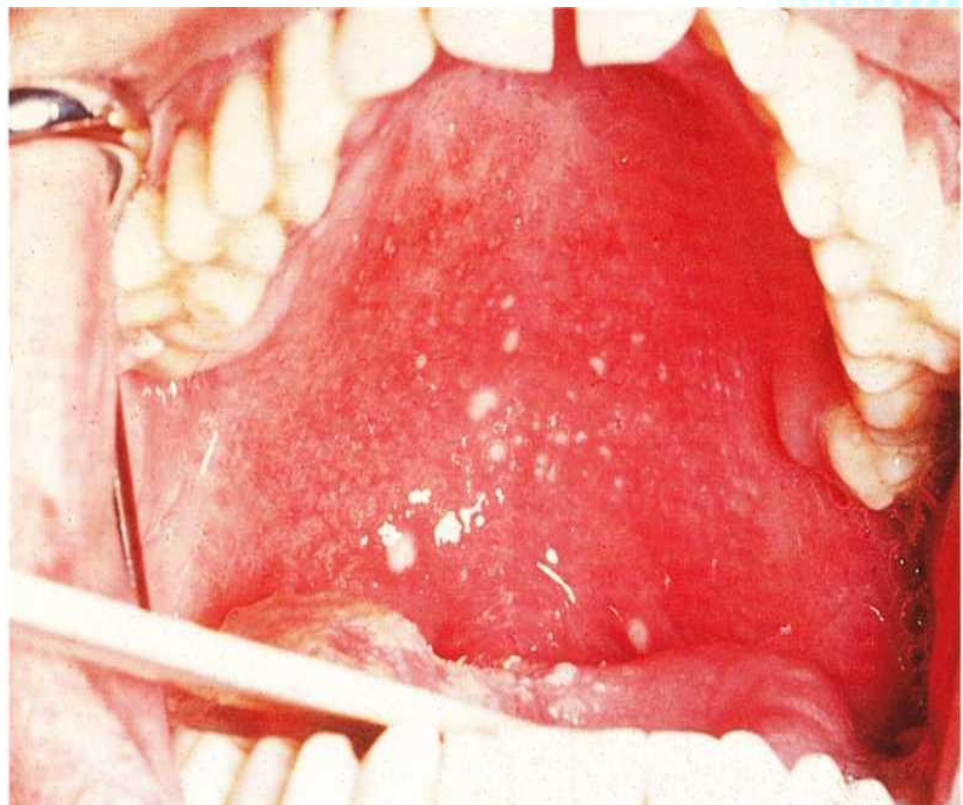


Fig. Candidiasis of the palate of a young patient undergoing antibacterial chemotherapy for bacterial tonsillitis.

The paint-drop-like deposits, which are removable pseudo membranes, consist of fungi threads (which attach to the epithelium and cause an inflammatory reaction) admixed with fibrin, granulocytes, desquamated epithelium, and food debris.

The development of these findings is favored by therapy that eliminates the regular oral flora, which are then replaced by the latent, available fungi (latent *Candida*).

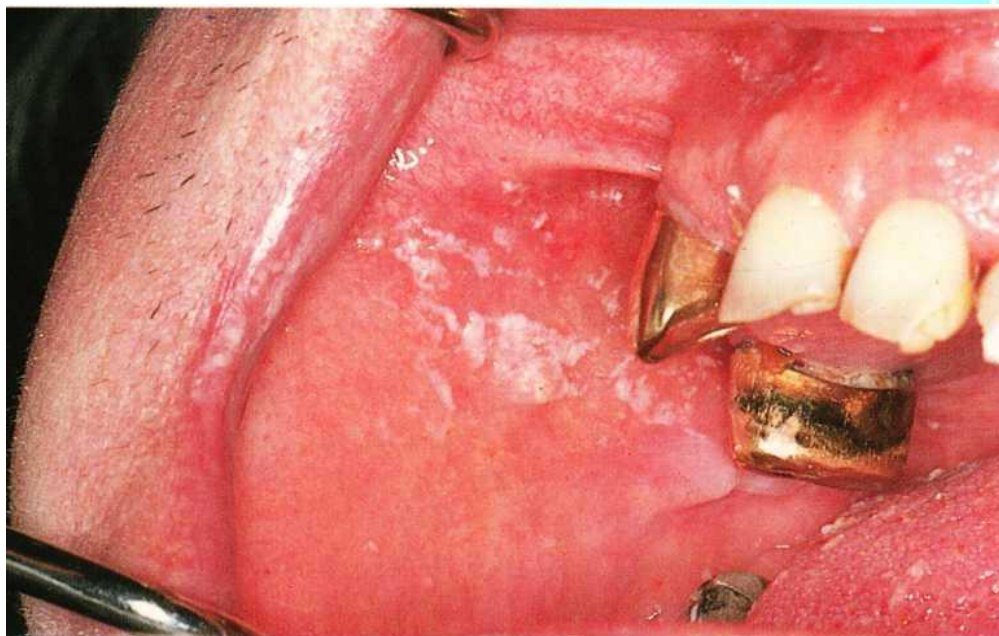


Fig. Pseudo membranous candidiasis of the oral cavity of a patient undergoing 10-day antibiotic therapy. Areas of predilection of this form of oral candidiasis are the cheeks, palate, and tongue. Predisposing factors are long-term treatment with antibiotics, corticosteroids, cytostatic and immunosuppressive agents, as well as serious diseases that compromise the immune system. The greater adhesion of the fungal pseudo-membrane and the greater the intensity of the mucosal erythema, the more severe the candidiasis. In this case, candidiasis is only the side effect of antibiotic treatment

Even local circumstances such as covering of the mucous membrane with a removable prosthesis especially in cases of poor oral hygiene, maceration of the skin of the lip commissures.

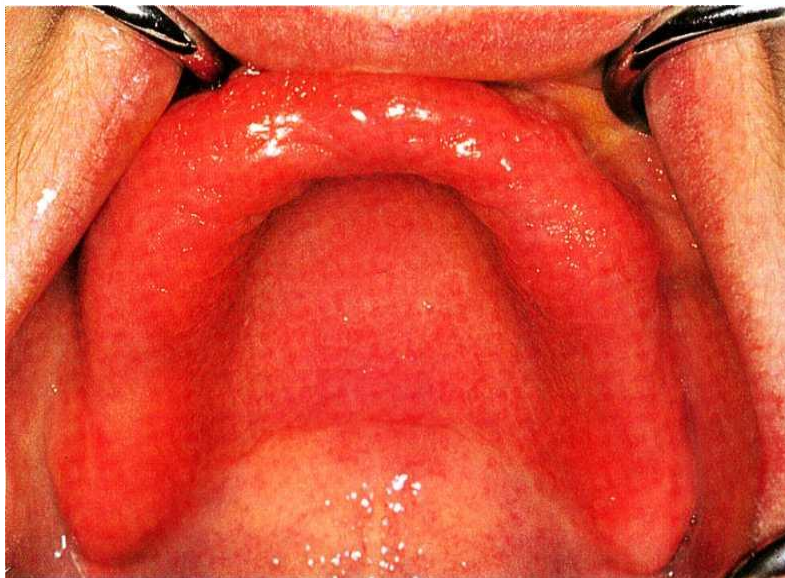
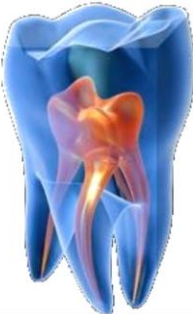

Fig. Denture stomatitis under complete prosthesis. Inflammatory mucosal changes under complete prostheses are found in 30% to 40% of all prosthesis wearers. Focal reddened spots and diffuse inflammatory reactions over the whole prosthesis area are observed particularly in the palatal mucosa.

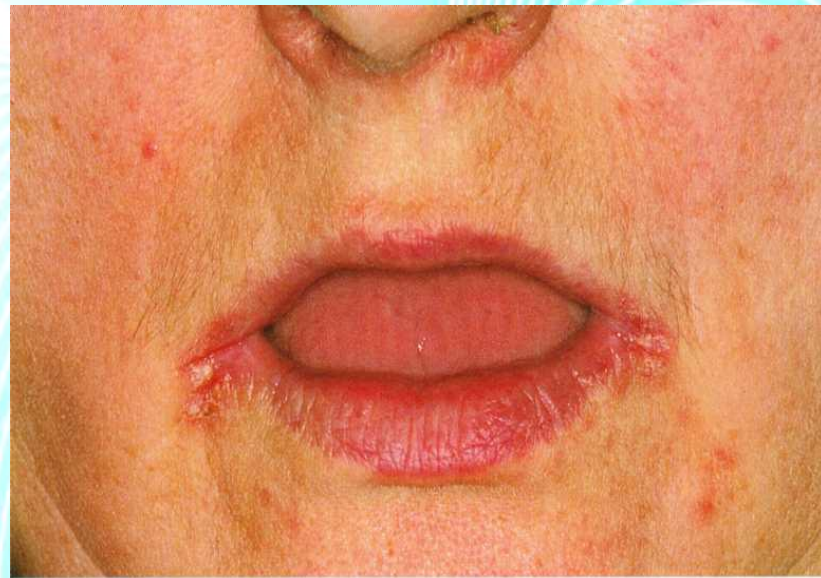

Fig. Chronic-atrophic form of interlabial mycosis caused by *Candida albicans* in a 63-year-old woman.

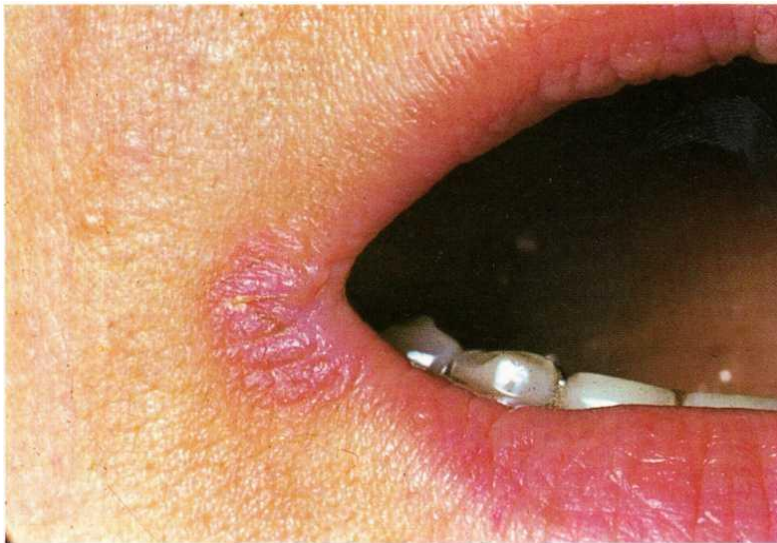
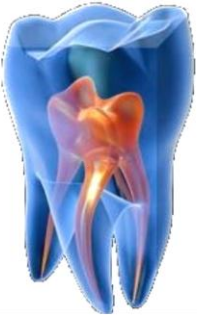

Fig. The well-demonstrated granulomatous tissue change has been present for 2 years. The local pathfinder in this case was the habit of constantly wetting the corner of the mouth with the tongue. As a facilitating systemic factor, it was possible to find a severe iron deficiency anemia. Diabetic metabolism disturbance as well as liver disease should be eliminated

Sweating, maceration and chafing, often occurring with diabetes mellitus, obesity and poor hygienic condition. These examples make clear that the physical and chemical disturbance of the integrity of the body can influence the equilibrium of the bacterial flora without a deficiency in the immune system.

Temporary or permanent immunologic defect of humoral or cellular defenses sooner or later regularly lead to opportunistic infection, so that the development of candidiasis.

Candidiasis in the oral cavity begins especially with HIV infection (dysfunction of immune system). As the immune defenses become more compromised, there is also a descending gastrointestinal tract Candidiasis, organ mycosis, and finally – a Candida sepsis.



Today in oral Candidiasis we differentiated:

- Pseudomembranous form;
- Erythematous (atrophic) form;
- Chronic hyperplastic form.

Clinical picture of the pseudomembranous form in the oral cavity

Consist white, raised spots.

- Flat Candida membranes over an infected red base (erythema) that can grow to a thickness of several millimeters.

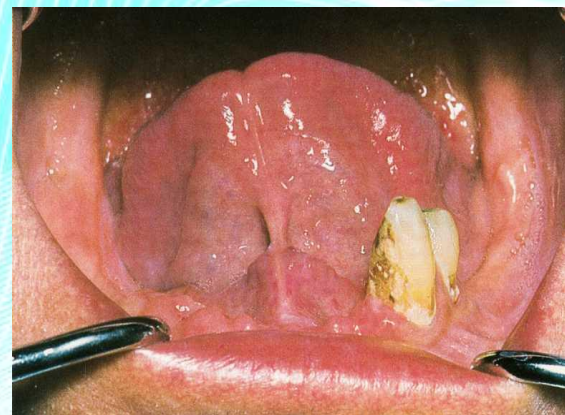
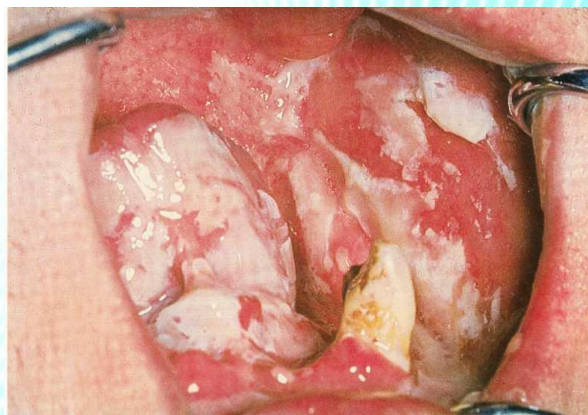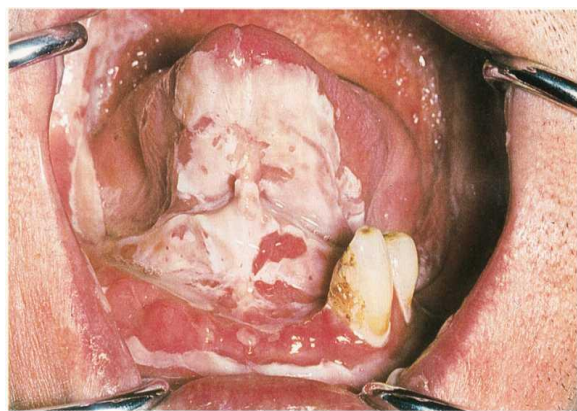

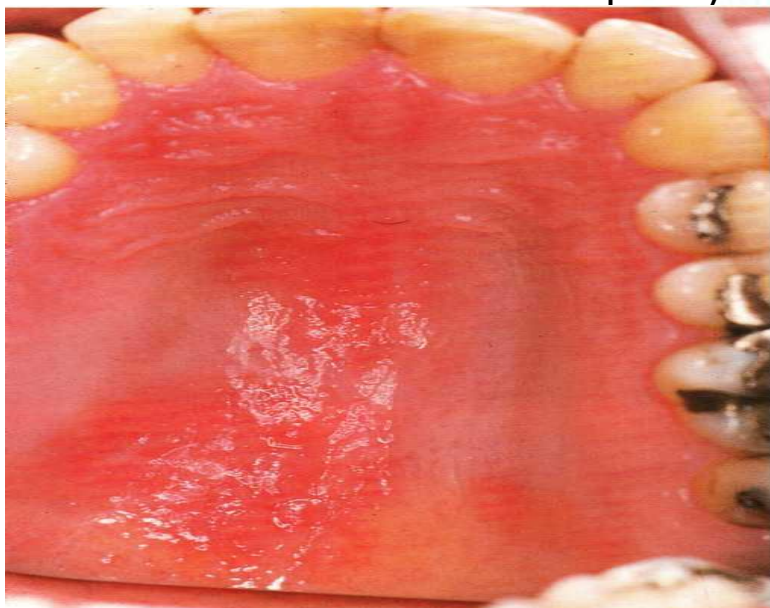
Fig. Severe acute pseudo membranous candidiasis in 57-year-old man

- They consist of a layer of matted threads of fungi together with desquamated epithelial cells, fibrin, granulocytes and food residue.



- The ends of the fungal threads only superficially adhere to the squamous epithelium, so that the brightly, pastellike coating of whitish-gray color. Can be wiped off without much injury and without selective bleeding from the mucous membrane.
- The thrush can spread to the pharynx and esophagus, and cause severe subjective symptoms with the development of erosions and ulcerations (which inhibit nutrient absorption).



Clinical picture of the Erythematous (atrophic) Candidiasis

- Is found particularly on the palate.
- Localization on the dorsum of the tongue leads to a loss of papillae.
- Candida – induced chronic changes most likely occurs at the corner of the mouth.
- Can be associated with a papillary variant on the hard palate under ill-fitting removable prosthesis (prosthesis stomatitis).

Fig. Erythematous (atrophic) candidiasis of the palatal mucosa. Together with hairy leukoplakia, this forms the first clinical sign of an HIV infection unknown to the patient. *Candida* infections are an important indicator of disturbed lymphocyte function and are found in almost all AIDS patients.

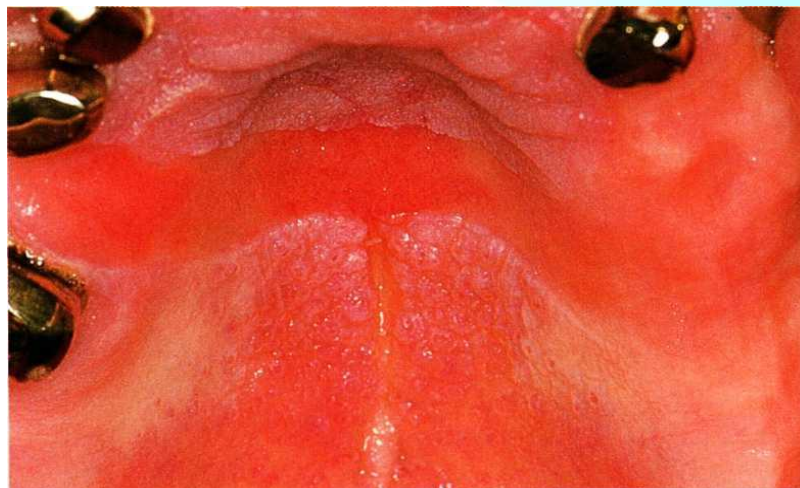


Fig. Denture stomatitis under a transverse connector.

The continuous nonphysiologic covering of the mucosal area by the prosthesis led to findings that included reddening (erythema) and atrophy of the mucosa, which occurs more frequently in the maxilla than mandible. In the multifactorial etiology, mechanical and microbiologic influences play a major role.

This emphasizes the importance of careful mouth and prosthetic hygiene. In some texts, the increased *Candida albicans* colonization under prostheses in patients with denture stomatitis is given such a high causal value that these disease findings are also called *chronic atrophic candidiasis* (ICD-DA 112.03).

The results of antimycotic therapy are, however, of little comfort. The original lesion probably requires another explanation. The covered mucosal region remains protected from the other changes, such as the smoker's leukokeratosis involving the remainder of the mucosa.



Chronic hyperplastic Candidiasis

- Present hard plaque like, sometimes even nodular or wart-forming lesions (resemble a Leukoplakia);
- Often associated with Leukoplakia.
- Are observed in areas of the corner of the mouth.
- Particularly observed in retro-angular areas
- In the fungi penetrate deeper in the sub epithelial tissue, depending on the immunologic conditions.
- It is more difficult to wipe of the fungi, and removal of the coating is associated with punctuate bleeding in this case.
- The mucosa shows varying degrees of inflammation and often granulomatous response
- The prognosis of these form is definitely less favorable.

With extension of the fungi into the blood vessels, hematogenous dissemination can develop – Candida Sepsis.

In case of serious immunodeficiency's (among them AIDS) a form of mucocutaneous mycosis can be caused by *Candida albicans*.

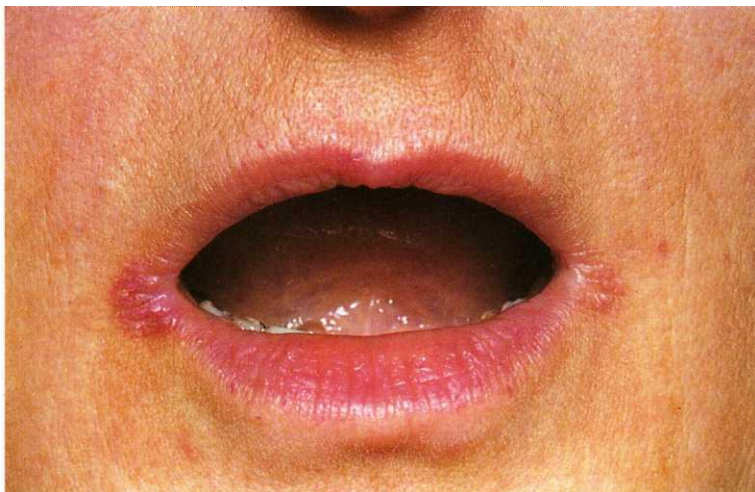

Fig. Chronic-hyperplastic form of interlabial mycosis caused by *Candida albicans* in a 48-year-old patient. In these cases, there is usually an associated systemic problem.

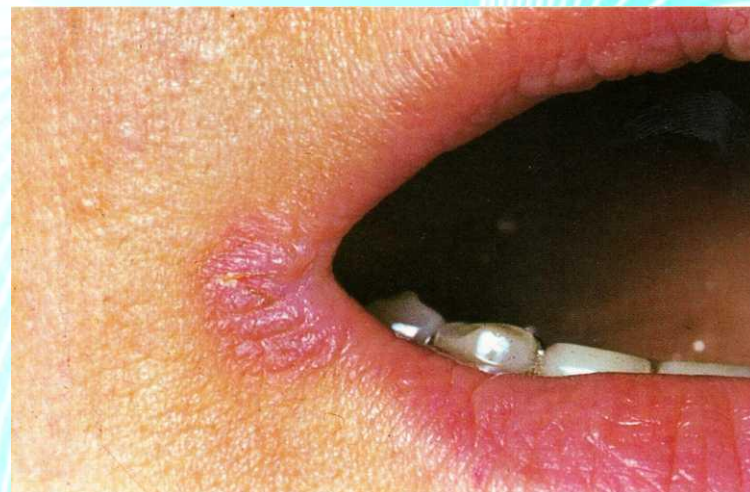


Fig. The well-demonstrated granulomatous tissue change has been present for 2 years. The local pathfinder in this case was the habit of constantly wetting the corner of the mouth with the tongue. As a facilitating systemic factor, it was possible to find a severe iron deficiency anemia. Diabetic metabolism disturbance as well as liver disease should be eliminated.

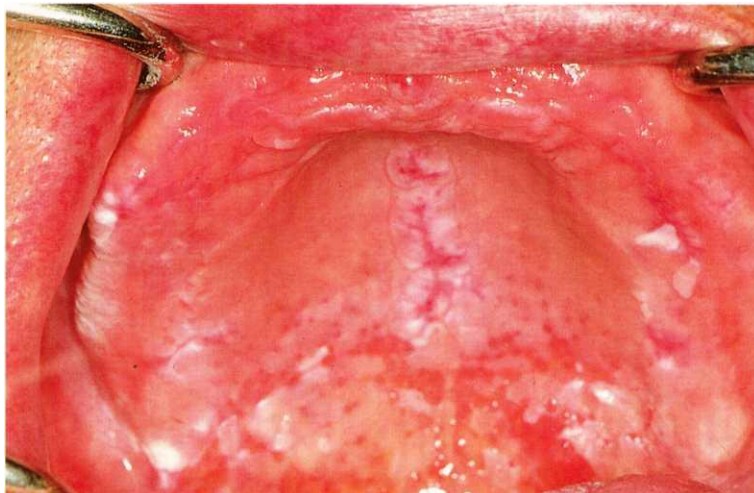


Fig. Chronic hyperplastic form of candidiasis of the palate in a wearer of complete dentures. The firm, in some areas wart-forming, plaques have a hard consistency. Note the scattered erythematous areas. This form of thrush mycosis, in its clinical picture resembles leukoplakia, with which it is often confused.

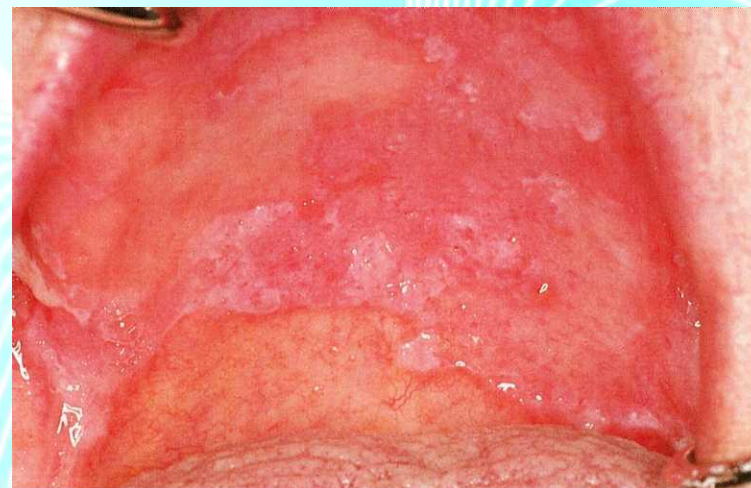
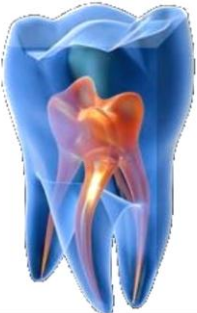
Fig. Histologically confirmed chronic hyperplasia.

LABORATORY DIAGNOSIS

For successful laboratory diagnosis of candidiasis is necessary to ensure the correct capture of the desired material from the patient.

The materials for the study can be: skin and nail flakes, separated lesions of the mucous membranes, pus, feces, urine, blood, bile, cerebrospinal fluid, tissue biopsy.



Materials that are delivered to the laboratory for examination in two directions:

- ❖ *smear microscopy, stained with methylene blue by Gram;*
- ❖ *crops on nutrient medium - agar Sabouraud, wort agar or candidates agar.*

Detection of a large number of budding cells pseudomycelium in native or stained - a valuable diagnostic finding. Single budding cells found in blood smears from the mucous membranes, have no diagnostic value, as identified hook and candidates carriers.

One-time allocation of the fungus Candida from the mucous membrane in an amount not to exceed 300 colonies per 1 ml is regarded as Candida carriage.

Detection at a large number of primary crop fungal cells (from 100 to 1000 cells or more in 1 ml wash) is interpreted as a sign of candidiasis.

The diagnosis is confirmed, if the re-seeding will be a marked increase in the number of fungi, even if the primary crop of mushrooms were few. Only quantitative research in the dynamics of the culture method makes a reliable support in the diagnosis of candidiasis.

Need to differentiate normal mushrooms stay in the human body from the pathological.

It is believed that the discovery of the fungus Candida in small amounts (up to 10 colonies in primary plated on a Petri dish) can be regarded as the norm.

Follow-up study of the same material in the dynamics of 5-7 days in healthy subjects in the negative or the same as the first crop, result.



If the number of colonies of fungi in the re-seeding grow to hundreds (100) of colonies, even in the absence of clinical signs of candidiasis should be considered this as a signal that requires further observation of the patient.

A lack of significant increase in the number of fungi in the re-seeding is diagnosed as Candida carriage.

Microscopy in pathological material visible rounded cells blastospory size 2-4 x 5-7 microns. Blastospory reproduce by budding from the mother cell. Blastospory at Candida fungal capable of filamentation (ie elongate and form a fiber - pseudomycelium).

Pseudomycelium differ from the true mycelium that do not shell share, it width of 1.5-2.5 mm. Pseudomycelium microscopy detection of pathological material is important for the laboratory confirmation of conclusions about fungical nature of yeast pathogen. Plated on liquid media growth of yeast colonies over 1000 per 1 g of the material suggests that the isolated fungi are the etiologic agent of the disease.

10-100 colonies per 1 g of the pathological material is not a criterion for the diagnosis of candidiasis, but only a signal to continue the search agent.

Sign of Candida is seeding from the mucous to 1000 cells in 1 ml wash with a tampon in the sputum - more than 500 cells in feces - more than 1000 cells in 1 g, in the bile - more than 300 cells in 1 ml.

The presence of the pathogen in all drugs in large quantities and active in combination with typical clinical picture indicates the presence of Candida infection in a patient.



For the diagnosis of Candida infections can be achieved with the serological tests, since fungi Candida full antigens are:

- ☐ *agglutination test;*
- ☐ *complement fixation;*
- ☐ *precipitation reaction;*
- ☐ *reaction of passive hemagglutination.*

Intradermal tests for fungal allergens with fungal antigens by the standard technique (intradermal intradaction) can detect hypersensitivity both immediate and delayed types.

DIFFERENTIAL DIAGNOSIS

Candidiasis should be differentiated:

- *with leukoplakia (verrucous and flat shape), for which the characteristic features are the clouding of the epithelium with clear boundaries, white spots and a whitish-gray color, not scraped. Verrucous leukoplakia develops in the given plane, the element of destruction - plaque protruding above the surrounding mucous membrane;*
- *with lichen planus (typical form), for which the characteristic features are papules whitish-gray color, which, when scared not be removed. Fused papules form specific openwork picture;*



- *with allergic stomatitis and allergic cheilitis, arising in response to entering allergens from the body, particularly in the contact of the oral mucosa with plastically mass, cosmetics, red portion of the lips with lipstick, chemicals, etc.,*
- *with their elimination clinical symptoms disappear completely, including redness, swelling, lichenification;*
- *with actinic cheilitis, which is characterized by symptoms are swelling, redness, erosion, cracks, scales and crusts, peeling in response to exposure to solar radiation;*
- *candidiasis'll pick - with streptococcal Zayed, for which the characteristic features are the large yellow "Honey" cover, they are partially scraped off, exposing the erosive weeping surface. Crusts appear on the lips, chin skin;*
- *with chronic recurrent aphthous stomatitis should differentiate acute pseudomembranous candidiasis (thrush). For the first characteristic clinical signs are aphthae, single, round, covered with fibrous coating, hard cleared when scraped and formed erosive bleeding surface;*



- with herpes simplex: the mucous membrane of the mouth and lip blisters, large coalesced bubbles subepithelial located, erosion covered with fibrous deposits, which could hardly be removed, exposing the bleeding erosive surface. Swelling and redness of the oral mucosa, catarrhal gingivitis, impaired general condition - fever, malaise, fatigue, headache;
- *a syphilitic papule, characterized by solitary papules on the skin and mucous membranes, the presence of seals at the base of the papules, in the discharge elimination of erosion found abundant pale treponema. Positive reaction by Wassermann;*
- *soft leukoplakia, in which the process is localized in the mucosa of the cheeks under the teeth line and the mucous lips, exfoliated epithelium and bites from habit to bite the oral mucosa, which becomes loose, whitish, swollen, covered with many scales. Mottled appearance of the surface of the mucous can compare it with the cloth, moth-eaten.*

TREATMENT

Treating candidiasis requires an individual approach to each case, as usually candidiasis develops as a secondary disease, caused by reduced immune defense, which may be due to different reasons. Therefore, the main trends in the treatment of a patient are:

- ☐ *identification of the etiologic factors underlying basis of pathogenesis of candidiasis in each individual case;*
- ☐ *Eliminate or reduce further the negative impact of these factors;*
- ☐ *pathogenetic therapy;*



Based on the failure of immune system (immunosuppression) for candidiasis, especially in chronic indolent forms, candida vaccine is recommended:

- ☐ *monovalent,*
- ☐ *polyvalent,*
- ☐ *autovaccine.*

With the same purpose in the arsenal of therapeutic agents with candidiasis can find a place:

- ❖ *pyrimidine derivatives - pentoksil 0.2 g 3 times a day for 3 weeks,*
- ❖ *methyluracil 0.5 x 3 times a day, course of treatment for 3-4 weeks.*
- ❖ *the drug stimulates the production of antibodies, phagocytic activity, stimulate leucopoiesis, increase the content of gamma globulin in the blood serum, increases regenerative capacity of tissues.*
- ❖ *the gamma globulin gistaglobulin, gistaglobin 2 ml 2 times a week for a course of injections 7 – 10 over 2-3 months - repeat the treatment.*
- ❖ *T-activin on 40 mcg a day, subcutaneously or intramuscularly, for 7-10 days.*
- ❖ *Kemantan 0.2 -- 3 times a day, for 14 days.*
- ❖ *Either diutsifon 0.1 -- 2 times a day for 6 days. Spend 2-3 course of treatment with interval ntervals of 1-3 days, under the control of biochemical and immunological blood.*
- ❖ *Levamisole (Decaris) 150 mg -- 1 time a day for 3 days, conduct two such courses at intervals of 3-6 days. After 2-3 months of treatment should be repeated;*



- ❖ tonic therapy that reduces mycotic sensitization, as well as stimulating nonspecific and specific resistance of the organism;
- ❖ inclusion in the complex treatment of antifungal drugs.
- ❖ Appointed diet with free of sweets and restriction of carbohydrates, rich in vitamins and proteins.

Polyene antibiotics:

- **nystatin**

- **levorin** of 500 thousand units. 4-8 times a day, so that the daily dose of 2-4 million units. preparation for a course of treatment - 56 million units. for 14 days. It is advisable to chew and suck the tablet because the digestive tract antibiotics are poorly absorbed. Regression of clinical symptoms of candidiasis has been observed for a 5-6 day reduced redness, swelling, rupture of the mucous membrane of the mouth, there is epithelialization erosion.

- **Amphotericin B** was administered in cases of lack of efficacy after application of nystatin, levorin. The dose is determined individually at the rate of 100-250 u / kg, the dose may be gradually increased up to 400-500 u / kg intravenously, the course of 20-25 injections. Similar action has Amphoglucaminum, the course of 14 days, to 600 thousand units., Up to 1 million units. a day.

- **Kanesten** 60 mg / kg, the treatment course of 10-14 days.

- **Dekamine** caramel 0.00015 grams to 1 caramel 6-8 times a day, a course of 11 days

- **Nizoral** on 2 tab. a day course of 10 days,

- **Lamisil** 250 mg per day, g / pc 2 weeks

- **Diflucan** 100 mg, 1 time a day, a course of 7-14 days.



- ❖ *multivitamin with trace elements, 2-3 pills a day for 1 month. B vitamins - B2, B6, C, PP, etc. Vitamin B2 (riboflavin) has some antifungal activity, regulates redox processes are involved in the carbohydrate, protein and fat metabolism.*
- ❖ *Calcium (calcium gluconate, calcium glycerophosphate, calcium lactate) as a tonic and giposen sibiliziruyuschie-take of 0.5 g 3 times a day for 1 month. Drugs pantothenic acid - calcium pantotent 0.1 g 3-4 times a day for 1 month.*
- ❖ *Iron supplements (pills ferropleks, konferon tablets DRI) for 1 month. Aloe with iron gemostimulin and other drugs, as it is proved that with candidiasis, a change in the exchange and impaired iron.*
- ❖ *desensitization therapy – dimedrol, suprastin, pipolfen, fenkarol for 1-1.5 months.*

Patients with long-term chronic forms of candidiasis will need continued taking sedatives and tranquilizers, psychotherapy, hypnosis. Good effect with auto-training and electro sleep.

Local treatment

Polyene antibiotics in the form of application to the mucous membrane of the mouth and lips is used every day, 3-4 times a day, treatment of 14 days. Can be assigned levorinovaya and nystatin ointment, clotrimazole and kanesten, mikoseptin and mikogeptin, amfoteritsin dekaminand ointments as a 20-minute applications.

To enhance the penetration of polyene antibiotics applicate previously wetted with 10% solution Dimexidum, top applied ointment base. Topical application of polyene antibiotics alters the permeability of cell cytoplasm, thereby fungicidal and fungistatic action.



Alkaline mouthwash - 2-4% solution of sodium bicarbonate, sodium tetraborate (borax), 2% boric acid solution that can stop the reproduction and growth of the fungus Candida.

Suspend the growth and reproduction of the fungus Candida iodine - 1% solution iodinol, 0.1% povidone iodine, Lugol's solution, which can be applied topically in the form of tushirovaniya mucosa.

Aniline colorants - 1.2% methylene blue, brilliant green, liquid Castellani, 1-2% solution of fuchsin, methylene violet, crystal violet, purple gentsianovi as colorate oral mucosa for 1-2 times a day, the drug has fungistatic effect, suspend the growth and reproduction of the fungus Candida.

Keratoplasticheskie drugs: Vinylinum, emulsion Teza, aloe juice and juice of Kalanchoe, vitamin A and E in the oil, rosehip oil, karotolin, olive oil and sea buckthorn oil, aekol, liniment aloe and liniment kalanchoe as applications to the mucous membrane of the mouth, 20 minutes 3-4 times a day, 4-5 days from the start of the general and local treatment of polyene antibiotics.

Conducted dental health, thorough removal of dental plaque, professional oral hygiene, replacement of old and inefficient prosthetic, rational prosthesis.



PREVENTION

Preventive maintenance should be performed in several ways.

1. *Reducing infection fungi Candida infants by detection and treatment of urogenital candidiasis and Candida carrier of pregnant women by assigning them to a narrow spectrum antibiotic action (penicillin, oxacillin, erythromycin).*

Detection and treatment of oral candidiasis of the mother, dental health. Sterilization nipple, pacifiers and other baby care items. The child must have an individual sterile container, her bed and linens, individual night vase.

Good hygiene measures and treatment in maternity hospitals, conducting proper handling equipment, baby clothes, the hands of medical staff, provision of sterile vials, pipettes, instruments, syringes and other things. Education nursing mothers breast care, nipples, hygienic manipulation.

2. *Rejection of irrational and massive antibiotic therapy, careful use of hormones under control and the treating physician (doctor).*

During prolonged antibiotic therapy is necessary to simultaneously assign polyene antibiotics inside, the course, adequate antibacterial. After the long anti-microbial therapy prescribe colibacterin and bifidumbakterin.



During prolonged antibiotic therapy is necessary to simultaneously assign polyene antibiotics inside, the course, adequate antibacterial. After the long anti-microbial therapy prescribe colibacterin and bifidumbakterin.

Severe general medical disorders must be accompanied by a comprehensive treatment should be prescribed large doses of vitamins, increase body resistance, the overall immune reactivity.

- 3. Early detection and treatment of dysbiosis (disbacteriosis).*
- 4. Implementation of sanitary and hygienic regime in the food industry, in production related to the possibility of infection by the fungus candida, as well as in health care in the performance of a variety of treatments, compliance with the skeletons of sterilization of instruments: tweezers, probes, mirrors, etc.*
- 5. Wide health education among the medical staff, employees of food companies, including population, expectant mothers and fathers.*

Children and adults should be aware that self-unsound, independent uncontrolled use of antibiotics and other drugs can lead to dysbiosis (disbacteriosis) and Candidiasis.



The End