

Periodontium. General notion. Anatomic and physiologic particularities of periodontal diseases. Classification of periodontal diseases.

Assistant professor Musteata Olesea  
2018

**Periodontium consists of the investing and supporting tissues of the tooth (gingiva, periodontal ligament, cementum, alveolar bone).**

**Cementum is considered a part of periodontium because along with the bone, it serves as the support for the fibers of the periodontal ligament.**

## **The gingiva**

**The oral mucosa consists of three zones:**

- gingiva and the covering of hard palate, termed masticatory mucosa;**
- dorsum of the tongue (ventral face), covered with specialized mucosa;**
- oral mucous membrane lining the remainder of oral cavity.**

**Gingiva is the part of oral mucosa that covers the alveolar processes of the jaws and surrounds the necks of the teeth.**

**Gingiva is divided anatomically into marginal, attached and interdental.**

**Marginal gingiva – the marginal or unattached, gingiva is the terminal edge or border of the gingiva surrounding the teeth like a collar. In about 50% of cases, it is demarcated from the adjacent attached gingiva by a shallow linear depression, the free gingival groove usually about 1 mm wide, the marginal gingiva forms the soft tissue wall of the gingival sulcus. It can be spread from the tooth surface with a periodontal probe.**

**Attached gingiva is continuous with the marginal gingiva. It is firm, resilient, and tightly bound to the underlying periosteum of alveolar bone. The width of the attached gingiva on the facial aspects differs in different areas of the mouth. It is generally greatest in the incisor region (3,5 to 4,5 mm in the maxilla and 3,3 to 3,9 mm in the mandible) and less in the posterior segments with the least width in the first premolar area (1,9 mm in the maxilla and 1,8 mm in the mandible). The palatal surface of the attached gingiva in the maxilla blends imperceptibly with the equally firm, resilient palatal mucosa.**

**Interdental gingiva occupies the gingival embrasure, which is the interproximal space beneath the area of tooth contact. The interdental gingiva can be pyramidal or have a “col” shape.**

**If a diastema is present, gingiva is firmly bound over the interdental bone and forms a smooth, rounded surface without interdental papillae.**

Fig.1 Diagram showing anatomic landmarks of gingiva

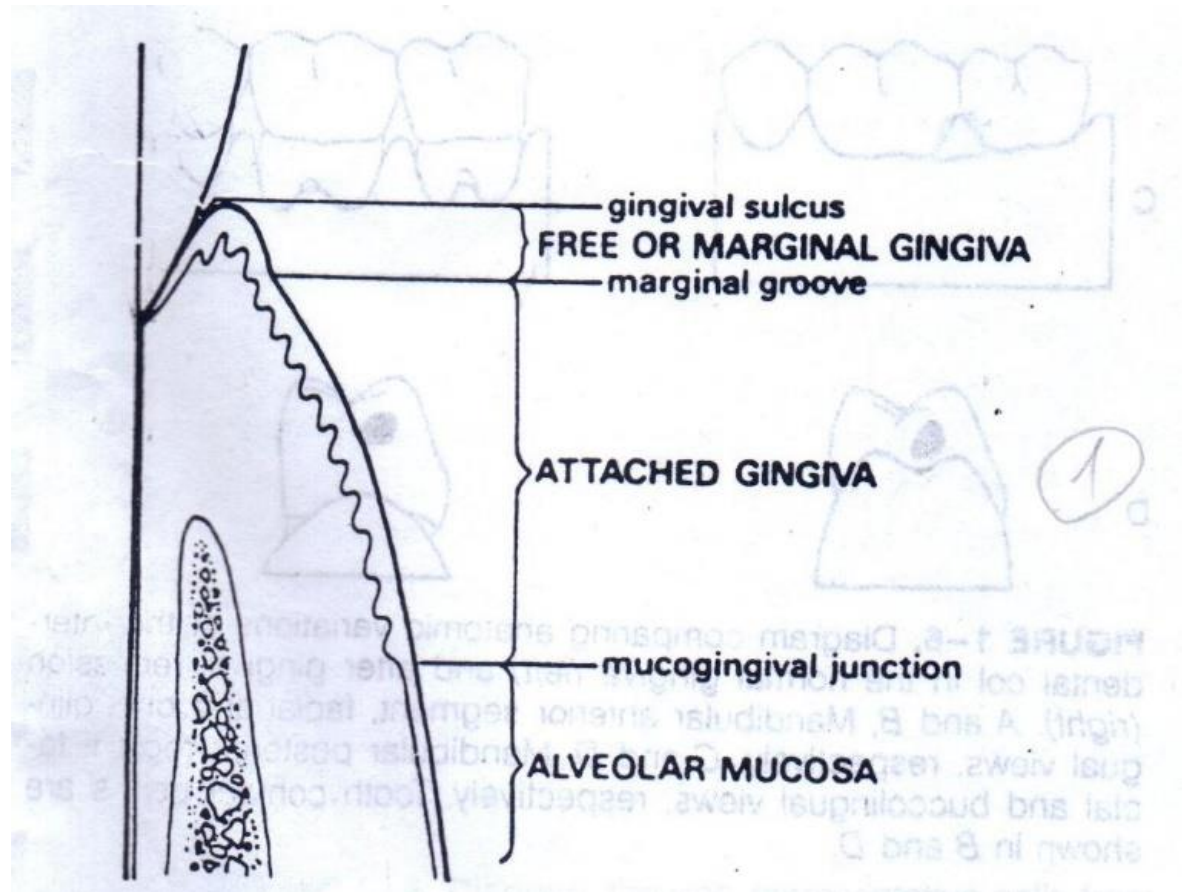


Fig.2 Schematic representation of gingival papilla. A. frontal zone; B. lateral zone.

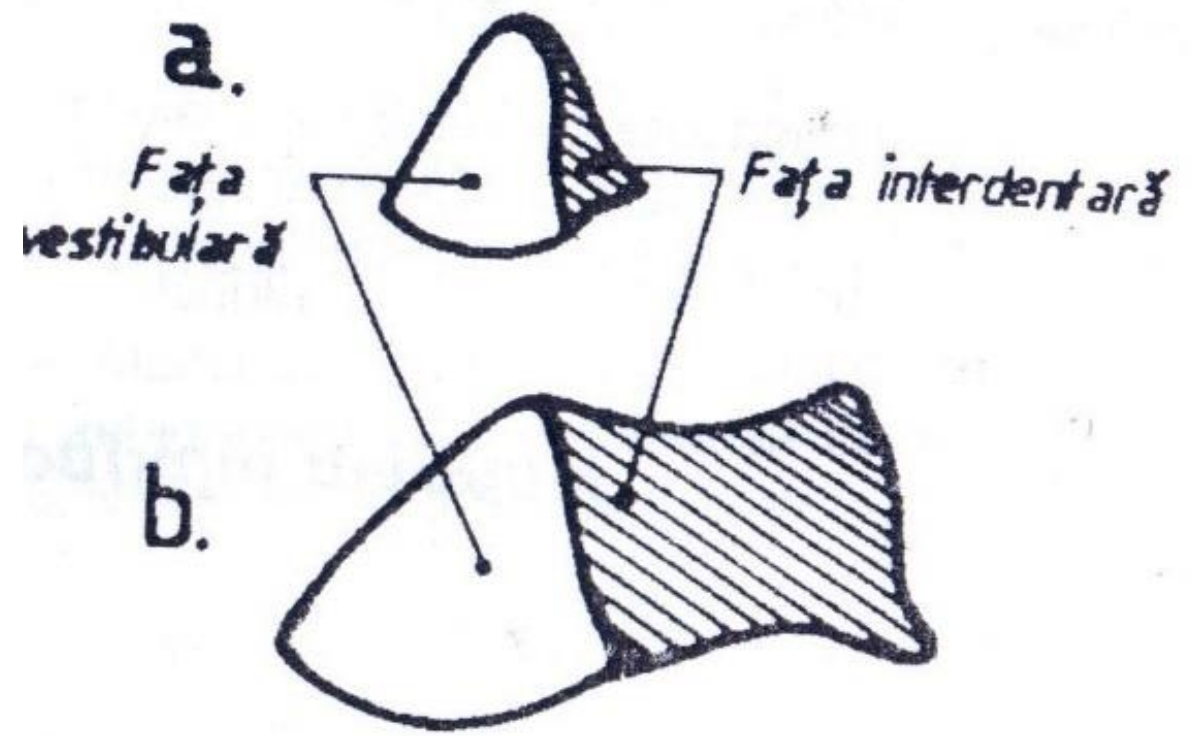


Fig.3. Principal components of marginal periodontium:

- EO-oral epitheliu;
- ES-sulcular epithelium;
- EJ-junctional epithelium;
- SG-gingival sulcus;
- CG-gingival corion;
- LS-supraalveolar ligamnetary system;
- C-radicular cement;
- D-desmodontium;
- LP-the system of periodontal ligaments;
- OAP-proper alveolar bone, lamina dura, lamina cribriforma, internal cortical;
- OAM-medular bone, trabecular bone;
- CE-external cortical.

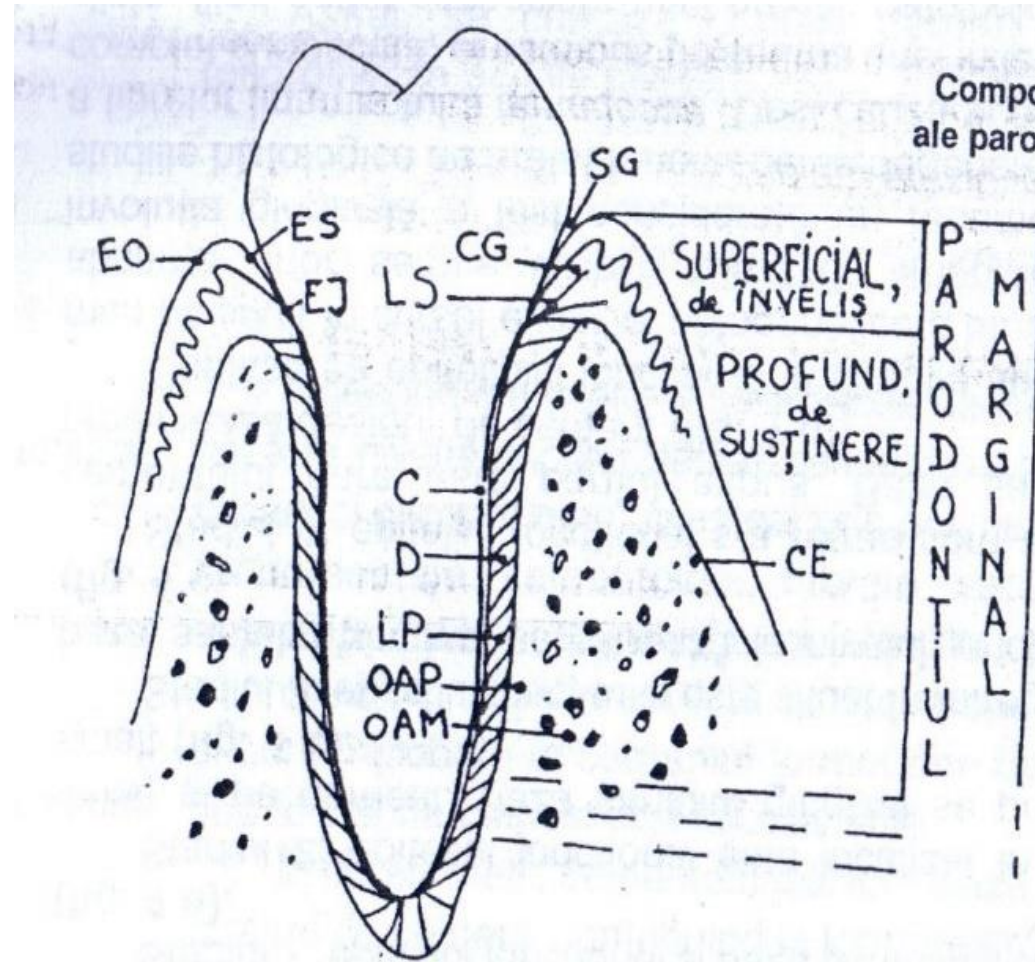
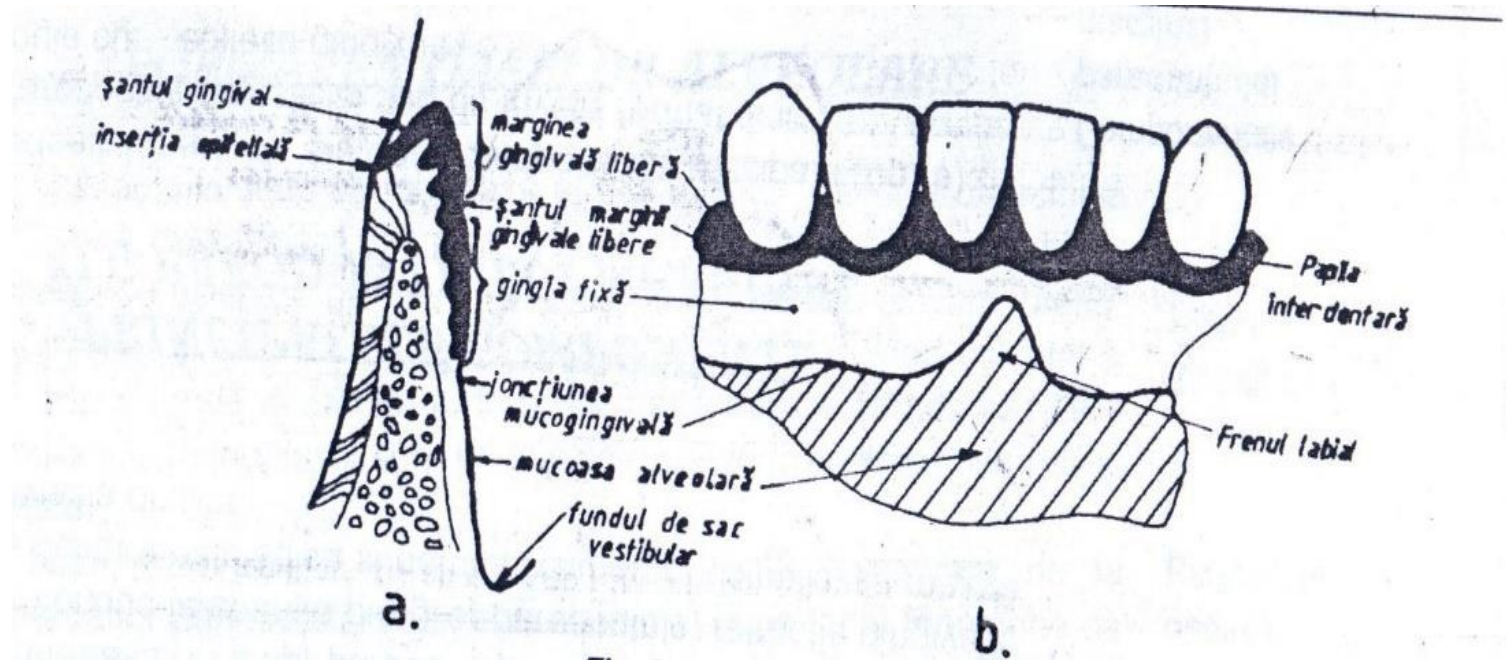


Fig. 5  
Componentele principale  
ale parodontiului marginal:

- EO = epiteliul oral;
- ES = epiteliul sulcular;
- EJ = epiteliul joncțional;
- SG = șanțul gingival;
- CG = corionul gingival;
- LS = sistemul ligamentelor supraalveolare;
- C = cementul radicular;
- D = desmodonțiul;
- LP = sistemul ligamentului periodontal;
- OAP = osul alveolar propriu-zis, lamina dura, lamina cribriforma, corticala internă;
- OAM = osul alveolar medular, osul trabecular;
- CE = corticala externă



Fig.4 Gingiva components in cross section and vestibular view.



## **Color of gingiva**

**The color of the attached and marginal gingivae is generally described as coral pink and is produced by vascular supply, the thickness and degree of keratinization of the epithelium, and the presence of pigment – containing cells. The color varies among persons it is lighter in blond individuals with a fair complexion than in dark - complexioned brunettes.**

**The alveolar mucosa is red, smooth and shiny rather pink and stippled. Melanin, a non-hemoglobin-derived brown pigment, is responsible for the normal pigmentation of the skin, gingiva, and remainder of the oral mucous membrane. Melanin pigmentation in the oral cavity is prominent in blacks and absent or severity diminished in albinos. According to Dummett, the distribution of oral pigmentation in blacks is as follows: gingiva-60%, hard palate-61%, mucous membrane-22%, tonque-15%. Gingival pigmentation occurs as a diffuse, deep purplish discoloration or as irregularly shaped brown and light brown patches.**

## **Size of gingiva**

**The size of gingiva corresponds to the sum total of the bulk of cellular and intercellular elements and their vascular supply. Alteration in size is a common feature of gingival disease.**

## **Contour**

**The contour shape of the gingiva varies considerably and depends on the shape of the teeth and their alignment in the arch, the location and size of the areas of proximal contact, and the dimensions of the facial and lingual gingival embrasures.**

**The marginal gingiva envelops the teeth in collar-like fashion and follows a scalloped outline on the facial and lingual surfaces. On teeth with mesiodistal convexity (e.g. maxillary canines) or teeth with labial version – the normal arcuate contour is accentuated. On the teeth in lingual version, the gingiva is horizontal and thickened.**

## **Shape**

**The shape of the interdental gingiva is governed by the contour of the proximal tooth surfaces and the location and shape of gingival embrasures.**

## **Consistency**

**The gingiva is firm and resilient, except movable free margin, tightly bound to the underlying bone.**

**The collagenous nature of the lamina propria and its contiguity with the mucoperiosteum of the alveolar bone, determine the firm consistency of the attached gingiva. The gingival fibers contribute to the firmness of the gingival margin.**

## **Surface texture**

**The gingival presents a textured surface like that of an orange peel and its referred to as being stippled.**

**The attached gingival is stippled, the margin is not.**

**The central portion of the interdental papillae is usually stippled, but the marginal borders are smooth. Stippling varies with age. It is absent in infancy, appears in some children at about 5 years of age, increases until adulthood, and frequency begins to disappear in old age.**

**Microscopically, stippling is produced by alternate rounded protuberances and depressions in the gingival surface. The papillary layer of the connective tissue projects into the elevations, and both the elevated and the depressed areas are covered by stratified squamous epithelium.**

**Stippling is a form of adaptive specialization or reinforcement for function.**

**Keratinization is considered to be a protective adaptation to function. It increases when the gingiva is stimulated by toothbrushing.**

**The gingiva consists of:**

- **Gingival epithelium;**
- **Gingival connective tissue;**
- **Gingival supraalveolar fibers.**

**Gingival epithelium**

**Gingival epithelium constitutes a continuous lining or stratified squamous epithelium, and the three different areas can be defined from the morphologic and functional point of view:**

- **The oral or outer epithelium;**
- **The sulcular epithelium;**
- **The junctional epithelium.**

**The principal cell type of the gingival epithelium is the keratinocyte, also other cells can be found clear cells or nonkeratinocytes: the Langerhans cells, the Merkel cells, the melanocytes.**

**The main function of the gingival epithelium is to protect the deep structures while allowing with the oral environment. This is achieved by proliferation and differentiation of the keratinocyte.**

**Proliferation – of keratinocytes takes place by mitosis in the basal layer and, less frequently, in the suprabasal layers, where a small proportion of cells remain as a proliferative compartment while a large number begin to migrate to the surface.**



**Differentiation – consists of a sequence of biochemical and morphologic events that occur in the cell as it migrates from the basal layer. A complete keratinization process leads to the production of an orthokeratinized superficial horny layer similar to that of the skin, with no nuclei in the stratum corneum and a well-defined stratum granulosum.**

**In parakeratinized epithelia, the stratum corneum retains pyknotic nuclei, and the keratohyalin granules are dispersed, not giving rise to a stratum granulosum. The nonkeratinized epithelium (although cytokeratins are the major component, as in the epithelia) has neither granulosum nor corneum stratum, and superficial cells have viable nuclei.**

Fig. 6. Gingival fiber representation of supraalveolar ligamentary system:

- DG-dento-gingival;
- DD-dento-dental;
- DP-dento-periosteal;
- DA-dento-alveolar;
- AG-alveolar-gingival;
- TG-transgingival;
- IG-intergingival;
- SC-halfcircular;
- C-circular;
- A,B –vestibular section;
- C-transversal section.

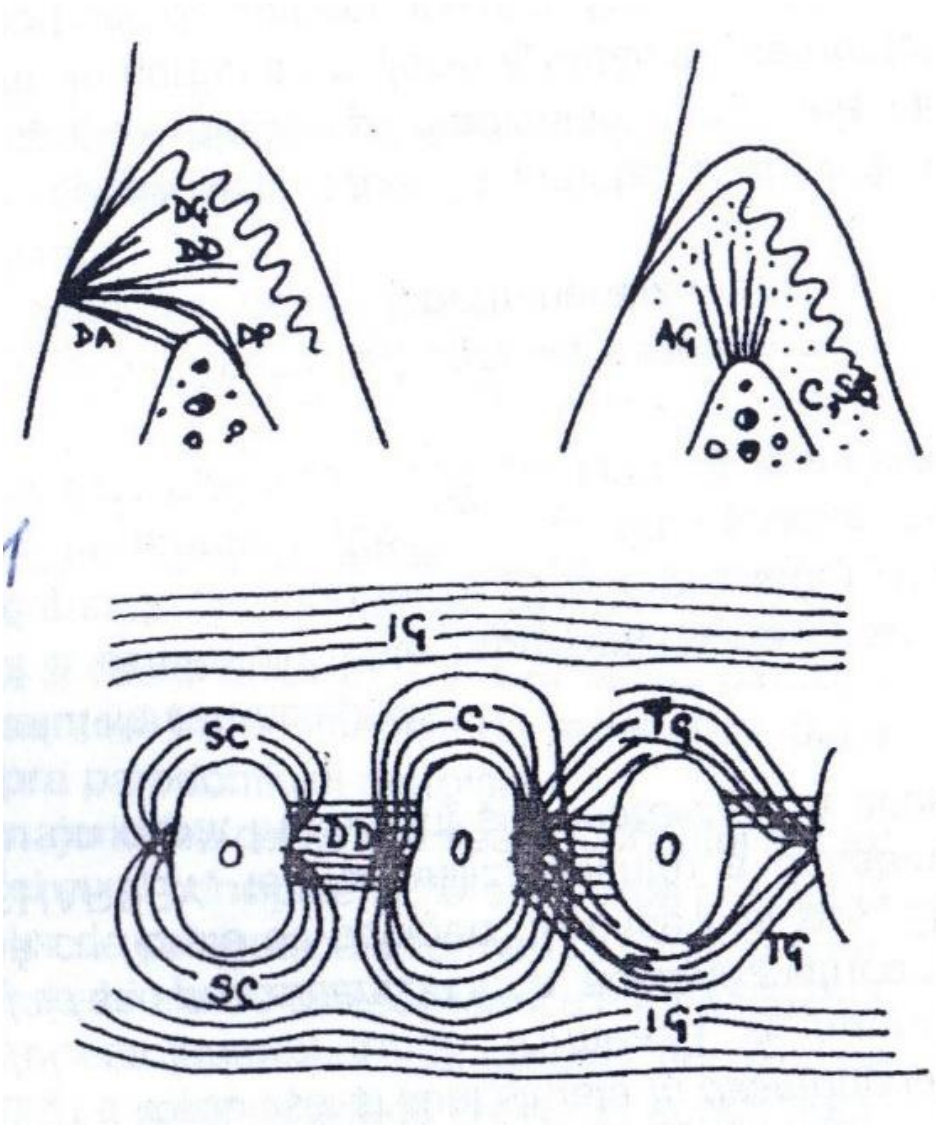
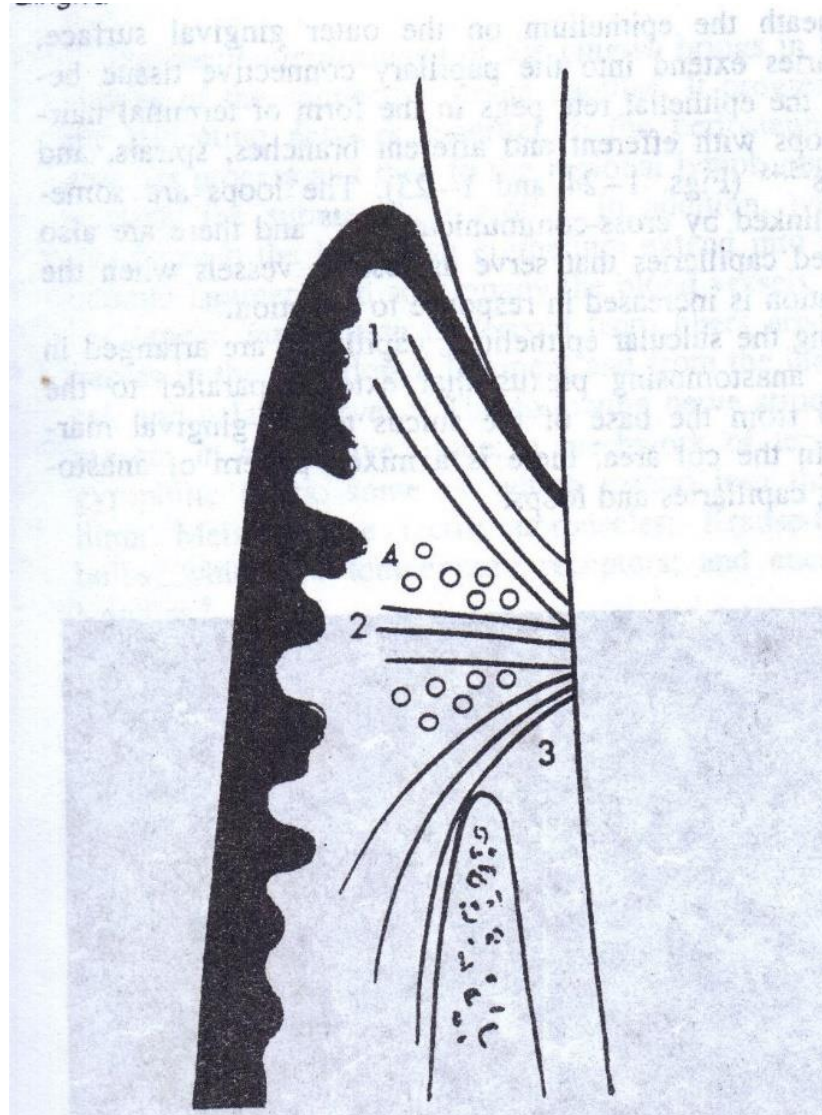


Fig.7. Diagram of gingivodental fibers extending from the cementum to the crest of the gingiva (1), to the outer surface (2), and external to the periosteum of the labial plate (3), circular fibers are shown in cross section(4).



**Marginal profound supporting (or  
functional) periodontium**

**The attachment apparatus of the tooth is composed from the periodontal ligament, cementum, alveolar bone.**

**1. Periodontal ligament. Periodontal ligament is the connective tissue of the gingival and communicates with the narrow spaces through vascular channels in the bone.**

**2. Periodontal fibers**

**The most important elements of the periodontal ligament are the principal fibers, which are collagenous, are arranged in bundles, and follow a wavy course when viewed in longitudinal sections. Terminal portions of the principal fibers that insert into cementum and bone are termed Sharpey's fibers.**

**Collagen is a protein composed from different aminoacids: glycine, proline, hydroxylysine, hydroxyproline.**

The amount of collagen in a tissue can be determined by its hydroxyproline content. Collagen biosynthesis occurs inside the fibroblasts to form tropocollagen molecules. These aggregate enter into microfibrils that are packed together to form fibrils. Collagen fibrils have a transverse striation with a characteristic periodicity of 64 nm; it is caused by the overlapping arrangement of the tropocollagen molecules. In collagen types I and III these fibrils associate to form fibers, and in collagen type I the fibers associate to form bundles.

Collagen is synthesized by fibroblast, chondroblasts, osteoblasts, odontoblasts. The principal fibers are composed mainly by collagen type I, whereas reticular fibers are collagen type III, type IV is found in the basal lamina. The molecular configuration of collagen fibers confers to them a tensile strength greater than that of steel.

**The principal fibers of the periodontal ligament are arranged in six groups: transseptal, alveolar crest, horizontal, oblique, apical, interradicular.**

- 1. Transseptal group – extends interproximally over the alveolar crest and are embedded in the cementum of adjacent teeth.**
- 2. Alveolar crest group – extends obliquely from the cementum just beneath the junctional epithelium to the alveolar crest. They prevent the extrusion of the tooth and resist lateral movements.**
- 3. Horizontal group – extends at right angles to the long axis of the tooth from the cementum to the alveolar bone.**

4. **Oblique group** – is the largest group in the periodontal ligament , extends from the cementum in a coronal direction obliquely to the bone. They bear the brunt of vertical masticatory stresses and transform them into tension on the alveolar bone.
5. **Apical group** – radiates from the cementum to the bone at the fundus of the socket. They do not occur on incompletely formed roots.
6. **Interradicular fibers** – fans out from the cementum to the tooth in the furcation areas of multiruted teeth.
7. **Periodontal ligament does not contain mature elastin, only two immature forms are found\$ oxytalan and eluanin. Oxytalan fibersrun parallelto the root surface to cementum in vertical direction and bend to attach to cementum in the cervical third of the root. Shackleford has described small collagen fibers in association with the larger principal collagen fibers, they run in all directions forming the indifferent fiber plexus.**



Fig.8.Representation of gingival fibers from the supraalveolar ligamentary system.

Fibers:

DG-dento-gingival;

DD-dento-dental or transseptal;

DP-dentoperiosteal;

DA-dento-alveolar;

AG-alveolar-gingival;

TG-transsgingival;

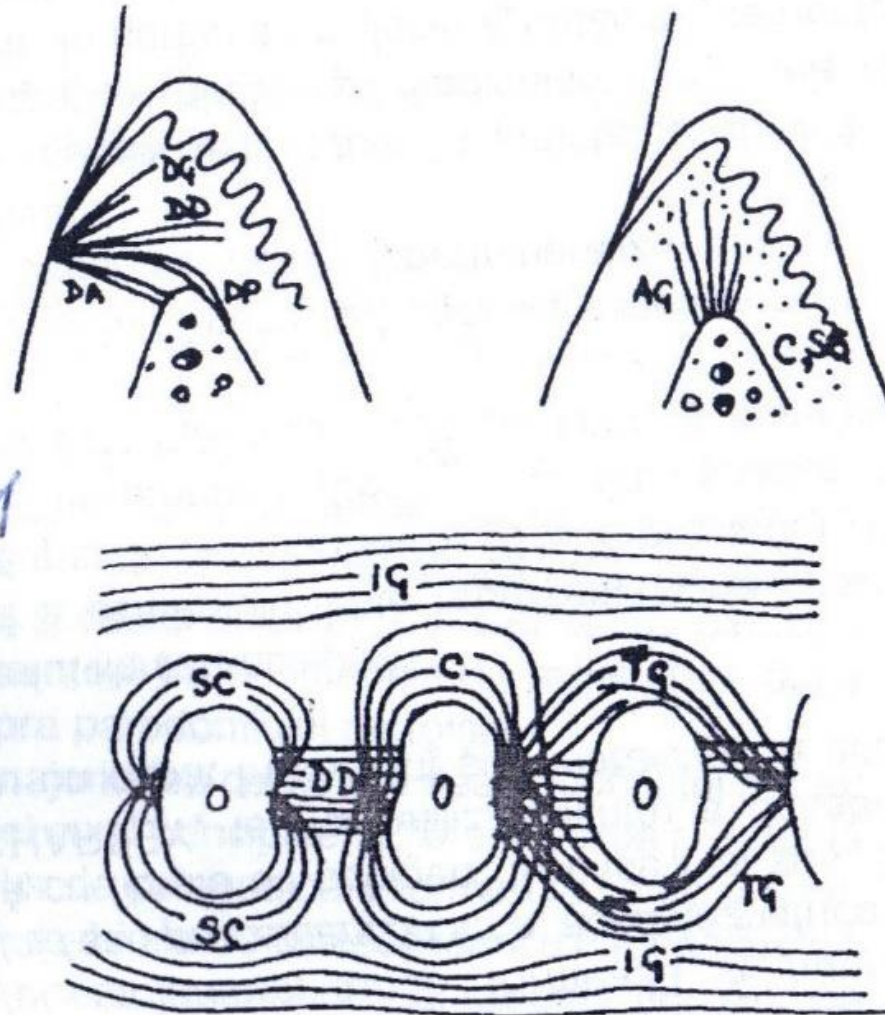
IG-intergingival;

SC- halfcircular;

C-circular;

A,B-vestibular-oral section;

C-transversal section.



## **Cellular elements**

**Four types of cells have been identified in the periodontal ligament:**

- **Connective tissue cells;**
  - **Epithelial rest cell;**
  - **Defense cells;**
  - **Cells associated with neurovascular elements.**
- 1. Connective tissue cells include fibroblasts, cementoblasts and osteoblasts, odontoclasts. Fibroblasts are the most common cells, appear as ovoid or elongated cells oriented along the principal fibers. These cells synthesize collagen, and they have capacity to phagocytose “old” collagen fibers and degrade them by enzyme hydrolysis.**

**2. The epithelial rests of Malassez form a lattice work, in the periodontal ligament and appear as either isolated clusters of cells or interlacing stands. The epithelial rests are considered to be remnants of Hertwig's root sheath, which disintegrates during root development. Epithelial rests are distributed close to the cementum of most teeth, and they proliferate when are stimulated and participate in the formation of periapical cysts and lateral root cysts.**

**3. The defence cells include macrophages, mast cells and eosinophils.**

## **Ground substance**

**The periodontal ligament also contains a large proportion of ground substance filling the spaces between fibers and cells. It consists of two main components: glycosaminoglycans (hyaluronic acid), proteoglycans, glycoproteins (fibronectin, laminin). It has also a high water content (70%), calcified masses called cementicles, which are adherent to or detached from the root surfaces. Cementicles may develop from calcified epithelial rests, around small spicules of cementum or alveolar bone traumatically displaced into the periodontal ligament, from the calcified Sharpe's fibers, and from calcified thrombosed vessels within the periodontal ligament.**

## **Functions of periodontal ligament:**

### **1. Physical function entail:**

- Provision of a soft tissue “casing” to protect the vessels and nerves from injury by mechanical forces;**
- Transmition of occlusal forces to the bone;**
- Attachment of the teeth to the bone;**
- Maintenance of the gingival tissues in their proper relationship to the teeth;**
- Resistance to the impact of occlusal forces (shock absorption);**

## **2. Resistance to the impact of occlusal forces (shock absorption) include three theories:**

- The tensional theory - the periodontal ligament has the major responsibility in supporting the tooth and transmitting forces to the bone. When a force is applied to the crown, the principal fibers first and straighten transmit forces to the alveolar bone, causing an elastic deformation of the bony socket, and the alveolar bone has reached its limit, the load is transmitted to the basal bone.**
- Viscoelastic system theory – considers the displacement of the tooth to be largely controlled by fluid movements with fibers having only a secondary role when forces are transmitted to the tooth, the extracellular fluid passes from the periodontal ligament into the narrow spaces of bone through foramina in the cortical layer this fluid is depleted and resorbed by fiber bundles. This leads to blood vessel stenosis.**

- **Thixotropic theory – claims that the periodontal ligament has the rheologic behavior of a thixotropic gel which gives changes in the viscosity of the biologic system.**

**3. Transmission of occlusal forces to the bone when an axial force is applied to a tooth, there is tendency toward displacement of the root into the alveola, the oblique fibers alter their wavy, assume their full length and sustain the major part of the axial force. When a horizontal or tipping force is applied there is an within movement and second a displacement of the facial and lingual bony plates.**

**4. Nutritional and sensory functions. The periodontal ligament is abundantly supplied with sensory nerve fibers capable of transmitting tactile, pressure, pain sensation by the trigeminal pathways.**

## **Classification of periodontal diseases (State Moscow Medical Institute Semashko)**

**1. Gingivitis – is the inflammation caused by harmful action of local factors and general without involving dento-gingival ligaments in this process.**

**Forms: catarrhal, ulcerative, hypertrophic.**

**Manifestation: mild, moderate, severe.**

**Evolution: acute, chronic, aggravated.**

**Spreading: localized, generalized.**



**2. periodontitis – is the inflammation of periodontal tissues with progressive destruction of periodontium and alveolar bone.**

**Manifestation: mild, moderate, severe.**

**Evolution: acute, chronic, aggravated, abscess, remission.**

**Spreading: localized, generalized.**

**3. Periodontosis – is the dystrophic lesion of periodontal tissue with a horizontal resorption of the bone.**

**Manifestation: mild, moderate, severe.**

**Evolution: chronic, remission.**

**Spreading: generalized.**

#### **4. Syndromes and early onset disease with progressive periodontal destruction of tissue:**

- Papillon-Lefevre syndrome;**
- Neutropenia;**
- Diabetes mellitus, decompensation form;**
- Agamaglobulinemia**

#### **5. Tumors – tumefaction disease:**

- Epulides;**
- Fibromatosis**