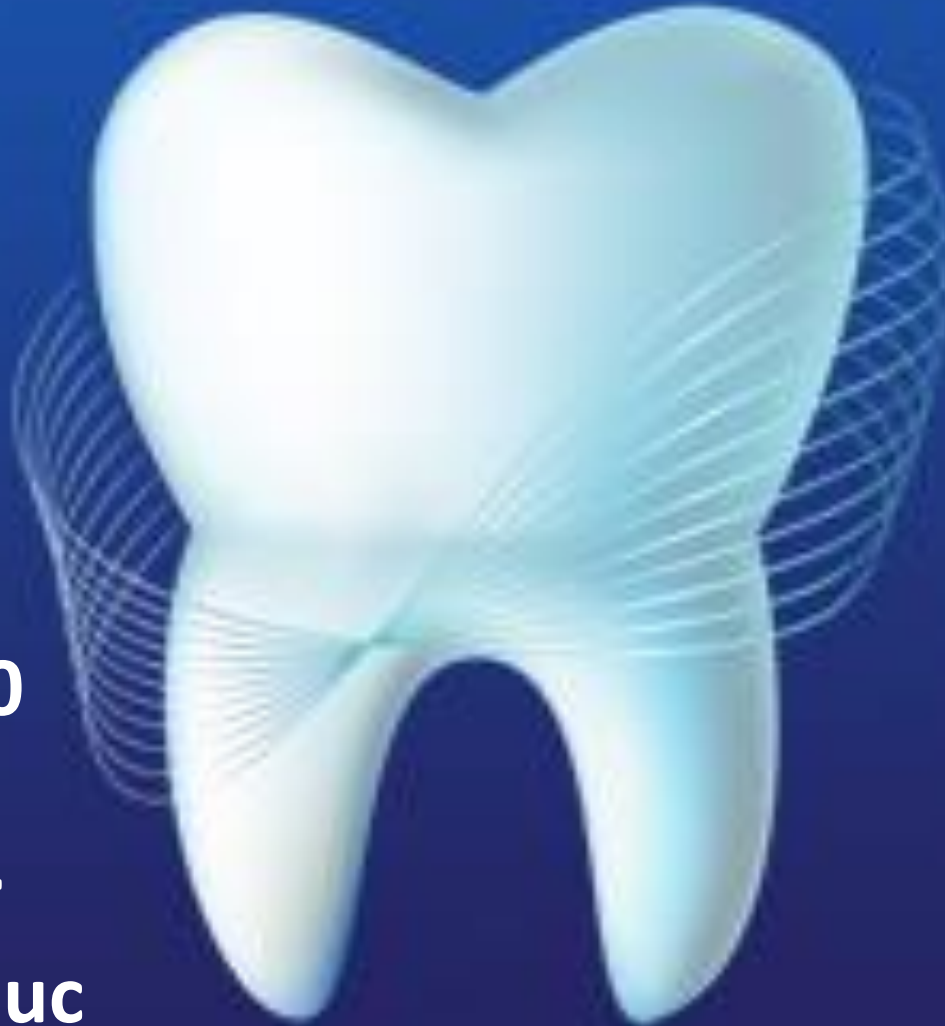

**MARGINAL PERIODONTITIS. NOTION. THE DEGREE OF MORBIDITY.
ETIOLOGY AND PATHOGENESIS. THE ROL OF LOCAL AND GENERAL FACTORS
IN EVOLUTION OF THIS PROCESS. CLINICAL FORMS OF MARGINAL
PERIODONTITIS. PROCESS GRAVITY. CLINICAL ASPECTS**

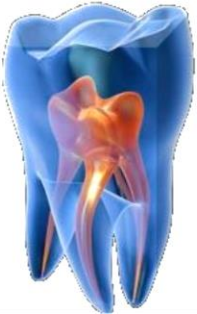

Lecture 9:10

4 Year

8 Semester

© V. Nicolaiciuc



The degree of morbidity

Periodontitis is defined as “an inflammatory disease of the supporting tissues of the teeth caused by specific microorganisms or groups of specific microorganisms, resulting in progressive destruction of the periodontal ligament and alveolar bone with pocket formation, recession or both”.

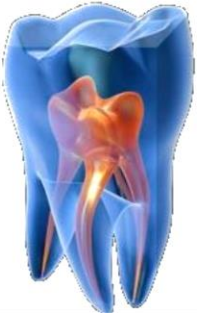How much chronic periodontitis is presents? The most recent date for the prevalence of periodontal diseases in the United State came from 1988 – 1994. The prevalence of periodontal attachment loss depends greatly on the threshold chosen, ranging from a high of 99% for a threshold of greater than 1mm to a low of 7% for a threshold of greater 7mm.

At the threshold of greater then 3mm, the prevalence of attachment loss in at least one site in the mouth was 53,1%.

The prevalence of attachment loss increased steadily with age, from a low of 35,7% for the 30 – to 39 year-old group to high of 89,2% for the 80 to 90 year-old group. On average per person, 19,6% of the teeth had attachment loss greater then 3mm.

Among people with at least one site of attachment loss greater then 3mm, an average of 36,6% of the teeth per person was affected. The mean percentage of teeth affected also increased with age.

Maxillary molars and mandibular incisors were more likely than other teeth to have attachment loss greater then 3mm, where’s maxillary central incisor were the least likely.



Generally, pockets greater than 3mm are considered to reflect disease. The prevalence of periodontal pockets greater than 4mm was 23.1%. The average extent of pockets greater than 4mm was 5.2% of teeth per person.

According to the WHO periodontal diseases are common among people of Earth. 80% of children suffer from gingivitis (10-20 year-olds). Pronounced changes in the periodontium destructive with involvement in the process of bone usually identified after 40 year-olds. According to the analysis of WHO in 35 countries collected in persons aged 31-44 years - defeated by 40 to 75% and above. About 90% of gingivitis is catarrhal gingivitis. Parodontozia – 4-5% from all lesion of parodontium.

Etiology and pathogenesis of periodontal diseases

As many as 600 different species of bacteria that colonize the oral cavity can affect the delicate balance of host-bacterial interactions leading to health or disease. Periodontal infection is initiated by specific invasive oral pathogens that colonize dental plaque biofilms on the tooth root surface.

Local and systemic factors can also modulate on individual's susceptibility to periodontitis. This chronic challenge of virulent microorganisms leads to destruction of tooth – supporting soft and hard tissues of the periodontium, including alveolar bone, tooth root cement, and periodontal ligament.



Although, periodontitis is initiated by the subgingival microbiota, it is generally accepted that mediators of connective tissue breakdown are generated to a large extent by the host's response to the pathogenic infection in a susceptible host, microbial virulent factors trigger the release of host – derived enzymes and pro inflammatory cytokines, that can lead to periodontal tissue destruction.

The implications of periodontal microbiota – associated by products such as endotoxins on induction of the innate immune response, toll – like receptor (TLR) signaling generation of pathogen associated molecular patterns (PAMPs), and their role in periodontal disease pathogenesis is crucial to the extent of disease severity.

Elevated levels of tissue – destructive enzymes such as collagenases and other host – derived proinflammatory cytokines, initiated by periodontal pathogens have been detected in inflamed gingiva and in oral fluids, such as gingival crevicular (sulcular) fluid and saliva.

[The role of host genes](#) in the etiology and pathogenesis of periodontal diseases is critically important to the determination of patient risk for periodontal tissue breakdown. Genetic test may prove useful for identifying patients who are most likely to develop disease, suffer from recurrent disease, or experience tooth loss as a result of disease.

The periodontitis represents a polygenic disease with multiple etiologies, with interaction with other chronic inflammatory illnesses.

Prevalence of Key-Pathogens in healthy subjects and patients with periodontitis.



Species	Health	Periodontitis
Actinobacillus actinomycetem comitans	12,8	31,0
Porphyromonas gingivales	10,6	59,5
Prevotella intermedia / nigrescens	69,1	87,9
Tannerella forsythia	47,9	90,5
Fusobacterium nucleatum	85,1	95,7
Peptostreptococcus micros	67,0	94,0
Campilobacter rectus	13,8	20,7

Will change that the disease will develop.

Clinical features picture of the periodontitis

Patient's complaints:

- Bleeding gums when brushing teeth;
- Bleeding gums when biting solid food;
- Odor from the mouth;
- Change the color of the gums;
- Change in the position of the teeth;
- The appearance of gaps between the teeth;
- Displacement of individual teeth;
- Pain in the gums;
- Difficulty in chewing;
- Loosening of teeth;
- Absence (loss) of the teeth.

Clinical signs the presence of periodontal pockets.

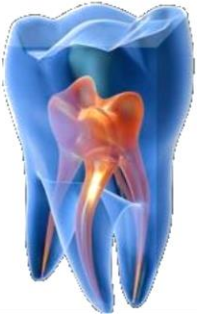Periodontal pockets – occurs with destruction of the supporting periodontal tissues. Progressive pocket deepening leads to destruction of the supporting periodontal tissues and loosening and exfoliation of the teeth.

Two types of periodontal pocket exist, as follows:

1. Suprabony (supracrestal or supra alveolar) in which the bottom of the pocket is coronal to the underlying alveolar bone.
2. Intra-bony (subcrestal, or intra alveolar) in which the bottom of the pocket is apical to the level of the adjacent alveolar bone (between the tooth surface and the alveolar bone).
3. Pockets can involve one, two, or more tooth surfaces and can be of different depths a types on different surfaces of the same tooth and on approximating surfaces of the same interdental space.

Clinical signs that suggest the presents of:

- ❖ Periodontal pocket include a bluish red, thickened marginal gingiva (depths a variable).
- ❖ Chronic inflammatory changes in the marginal gingiva.
- ❖ A bluish red vertical zone from the gingival margin to the alveolar mucosa.
- ❖ Gingival bleeding and suppuration.
- ❖ Tooth mobility.
- ❖ Diastema formation.
- ❖ Symptoms such as localized pain, or pain “deep in the bone”.
- ❖ Supragingival and subgingival plaque accumulation (calculus formation).





- ❖Gingival inflammation.
- ❖Diagnosed radio graphically by evidence of bone loss.
- ❖Loss alveolar bone.
- ❖Poor oral hygiene.
- ❖Blunted or rolled gingival margins.
- ❖Flattened or cratered papillae.
- ❖Bleeding either spontaneous or in response to probing.
- ❖Horizontal and vertical bone loss can be found.
- ❖Tooth mobility after appears.
- ❖Loss of clinical attachment.

Method of locating periodontal pockets and determining their extent is careful probing of the gingival margin along each tooth surface. In the inflammatory fluid and cellular exudates predominate, the pocket wall is bluish red, soft, spongy, and friable, with a smooth, shiny surface.



Fig. Limitations in periodontal probing – determination their extent



Periodontal pocket contain debris consisting:

- ❖ principally of microorganisms and their products:
 - enzymes,
 - endotoxin,
 - other metabolic products),
- ❖ gingival fluid,
- ❖ food remnants,
- ❖ salivary mucin,
- ❖ desquamated epithelial cells,
- ❖ leukocytes.

Plaque covered calculus usually projects from the tooth surface. Purulent exudates, if present, consist of living, degenerated and necrotic leukocytes.

Living and dead bacteria, serum and a scant amount of fibrin. The contents of periodontal pocket is toxic.

Periodontal disease activity

My be periods of remission - are characterized by a reduced inflammatory response and little or no loss of bone an connective tissue attachment.

Period of exacerbation – in which bone an connective tissue attachment are lost and the pocket deepens. This period may last for days, weeks, or months an is eventually followed by a period of remission. That bone loss occurs in episodic manners.



Active periods – show bleeding either spontaneously or with probing, the pocket epithelium appears thin and ulcerated. Overtime loss of bone should be detected **radio graphically**. We have a **horizontal** pattern of bone loss (the bone is reduced in height, but the bone margin remains approximately perpendicular to the tooth surface). **Angular** bone defect (result of vertical bone loss).

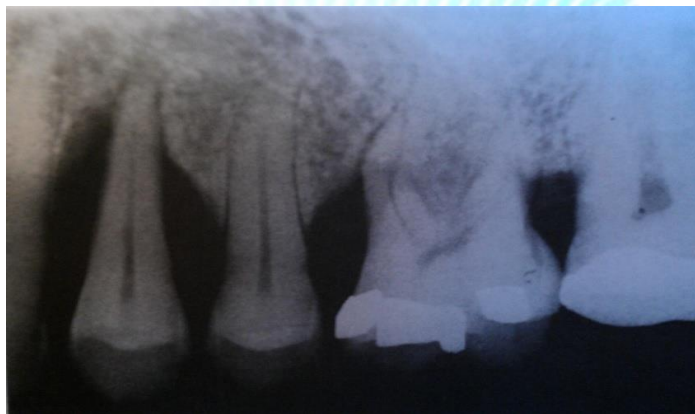


Fig. Angular (vertical) defects of different depths

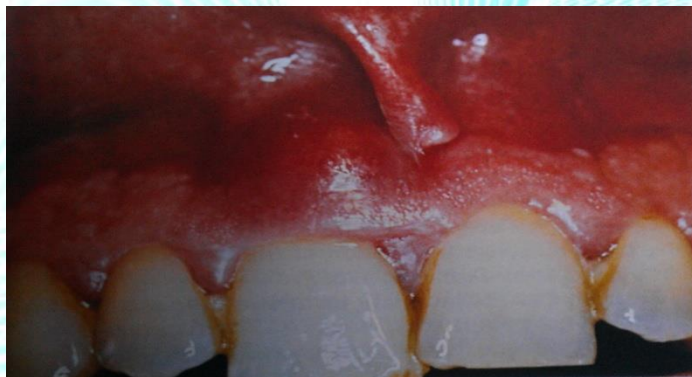

Fig. Periodontal abscess on an upper right central incisor



Periodontal abscess – is a localized purulent inflammation in the periodontal tissues.

Furcation involvement – have been classified as grades I, II, III, IV according to the amount of tissue distraction.

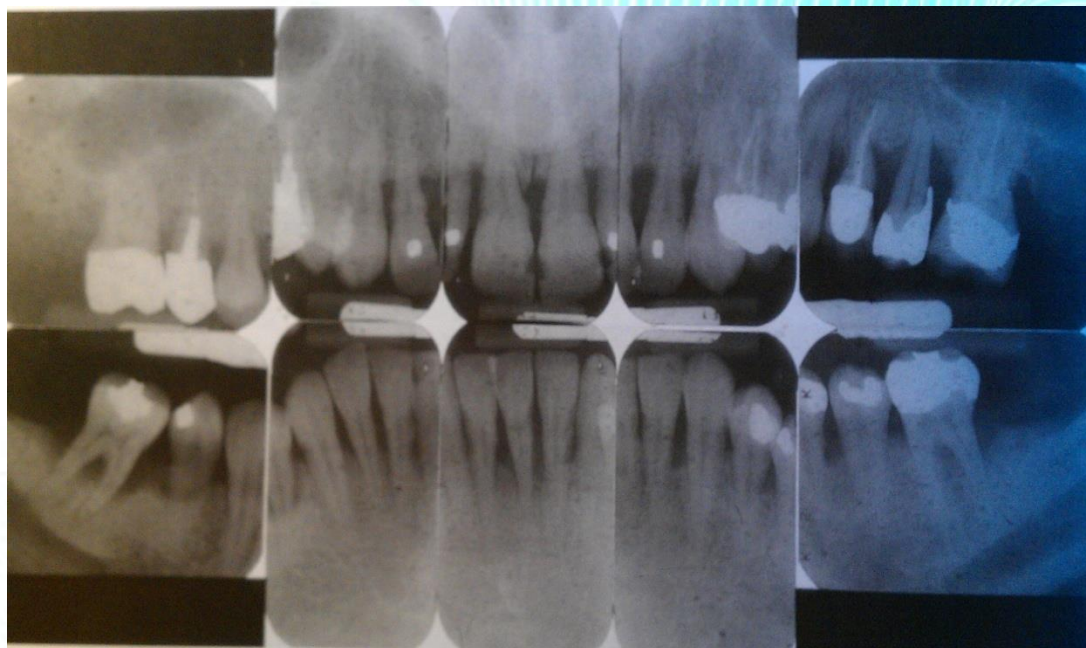
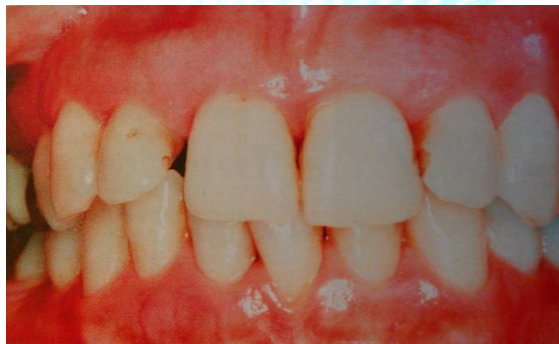

Fig. X-Rays showing severe, generalized, horizontal pattern of bone loss



Grade I – incipient bone loss.

Grade II – is partial bone loss (cool-de-sac).

Grade III – is total bone loss with through and through opening of the Furcation.

Grade IV – is similar to Grade III, but with gingival recession exposing the Furcation of view.

Diseases Severity The severity of destruction of the periodontium that occurs as a result of chronic periodontitis generally considered a function of time. With increasing age, attachment loss and bone loss become more prevalent and more severe because of an accumulation of destruction.

Disease severity may be described as being:

- Slight (mild) periodontitis;
- Moderate periodontitis;
- Sever periodontitis.

Slight (mild) periodontitis – periodontal destruction is generally considered slight when no more than 1 to 2mm of clinical attachment loss has occurred.

Moderate periodontitis - periodontal destruction is generally considered moderate when 3 to 4mm of clinical attachment loss has occurred.

Sever periodontitis - periodontal destruction is considered sever when 5mm or more of clinincal attachment loss has occurred.



Aggressive periodontitis (AP)

AP generally affected systemically healthy individuals less than 30 year-old, although patient may be older.

- ❖ Presents of deep periodontal pockets.
- ❖ Advanced bone loss.
- ❖ Amount of plaque on the affected teeth.
- ❖ Amount of periodontal destruction present.
- ❖ Aggressive periodontitis progressed rapidly.
- ❖ Disto-labial migration of the maxillary incisors.
- ❖ Diastema formation.
- ❖ Increasing mobility of the maxillary and mandibular incisors and first molar.
- ❖ Sensitivity of denuded root surfaces to thermal and tactile stimuli.
- ❖ Deep, dull, radiating pain during mastication (caused by irritation of supporting structures by mobile teeth and impacted food).
- ❖ Periodontal abscesses may for.
- ❖ Regional lymph node enlargement may occur.

Radiographic findings

- ❖ Vertical loss of alveolar bone around the first molars and incisors, beginning around puberty in other with healthy teenagers (is a classic diagnostic sign).
- ❖ “Arc-shaped” loss of alveolar bone extending from the distal surface of the second premolar to the mesial surface of the second molar.

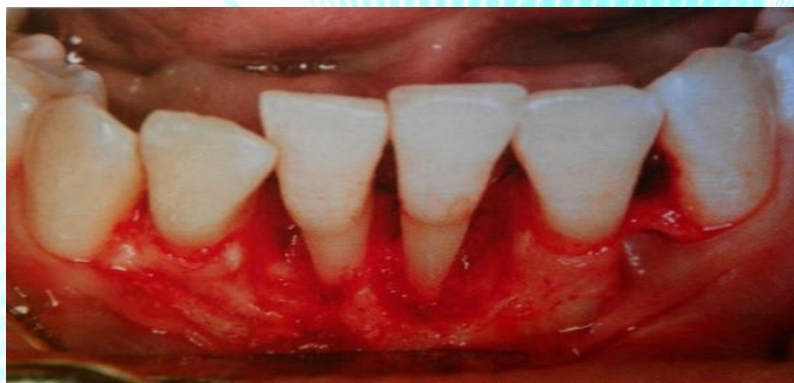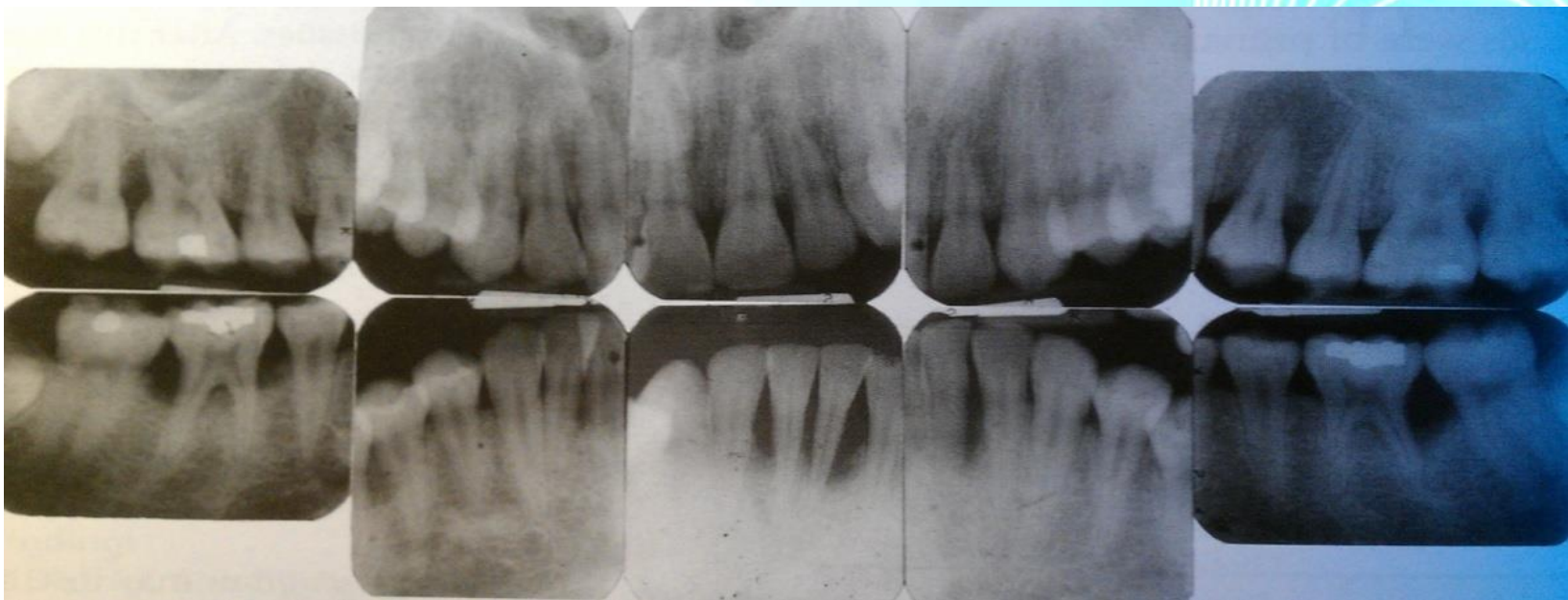


Fig. X-Rays showing localized vertical angular bone loss

- ❖ Bone defects are usually wider than usually seen with chronic periodontitis.
- ❖ In generalized aggressive periodontitis –sever bone loss associated with the minimal number of teeth. Affecting the majority of teeth in the dentition.

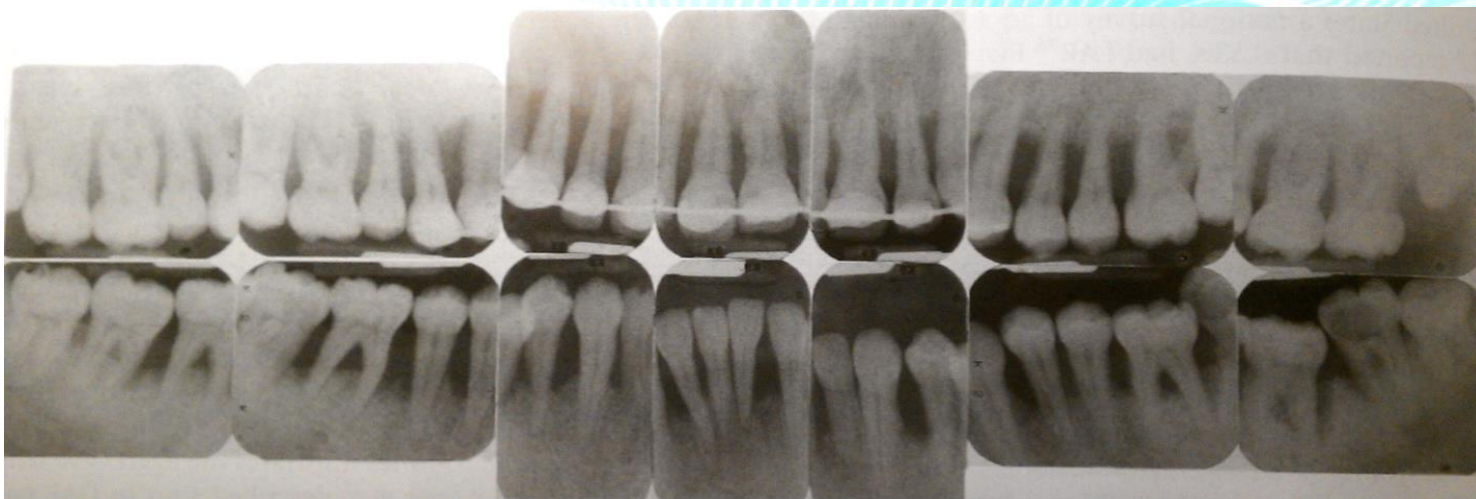
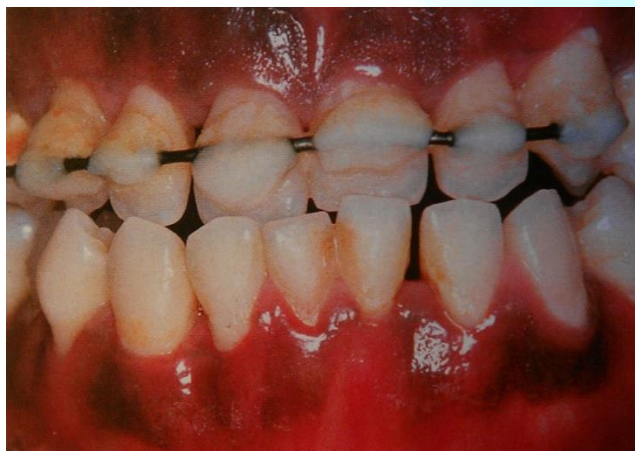
Fig. Severe generalized aggressive periodontitis (early tooth loss in 22 year-old)



Chronically slight (mild) periodontitis - on X-rays is determined – I - Degree of destruction of bone tissue of interdental septa: the absence of a compact plate, resorption of interdental septa top up to one per third ($1/3$) value, foci of osteoporosis.

Chronically moderate periodontitis – the x-ray destruction of interdental septa reaches half ($1/2$) the length of the teeth roots.

Chronically sever periodontitis – the x-ray destruction of bone tissue, resorption is more than half ($1/2$) or two third ($2/3$) the length of the teeth roots.



The End