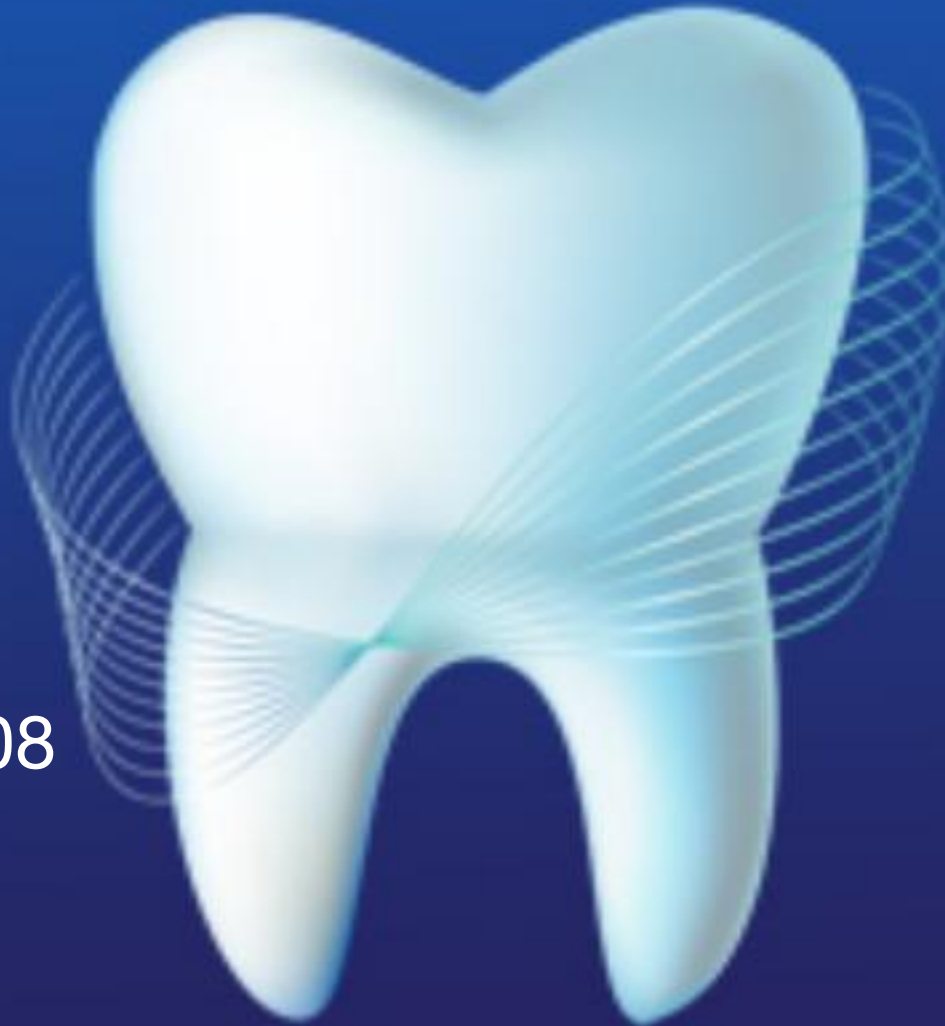
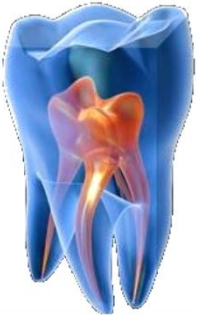
GINGIVITIS: CATARRHAL, NECROTIZING ULCERATIVE,
DESQUAMATIVE. ETIOLOGY AND PATHOGENESIS.
CLINICAL PICTURE, DIAGNOSIS AND DIFFERENTIAL
DIAGNOSIS. TREATMENT. PROPHYLAXIS



Lectures 07:08
4 Year
8 Semester
© V.



NECROTIZING ULCERATIVE GINGIVITIS (NUG)

Necrotizing ulcerative gingivitis (NUG) – is a microbial disease of the gingiva. It is characterized by the death and sloughing of gingival tissue and present with characteristic signs and symptoms.

Clinical features. NUG is usually identified as an acute disease. Involvement may be limited to a single tooth or group of teeth, or may be widespread throughout the mouth NUG can cause tissue destruction involving the periodontal attachment apparatus, especially in patients with long standing disease or severe immune suppression. When bone loss occurs, the condition is called necrotizing ulcerative periodontitis (NUP).

History. NUG is characterized by sudden onset of symptoms, sometime following an episode debilitating disease of acute respiratory tract infection. A change in living habits, protracted work without adequate rest, poor nutrition, tobacco use, and psychology stress are frequent features of the patient's history.

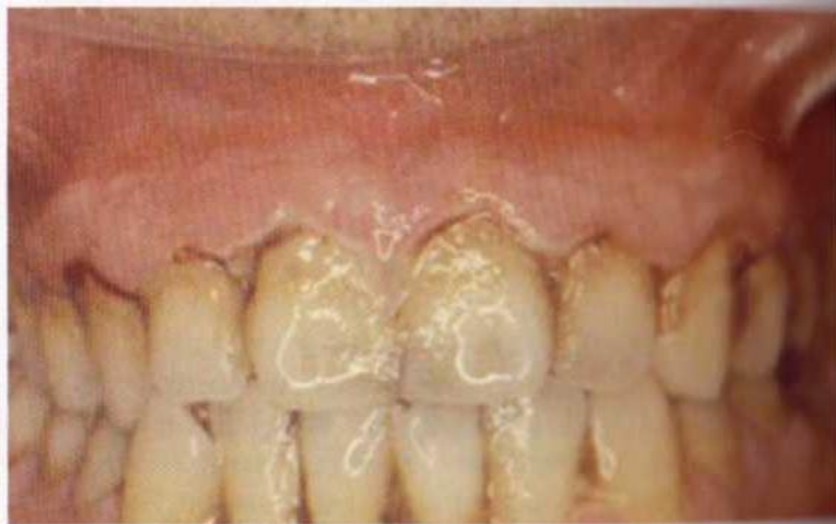
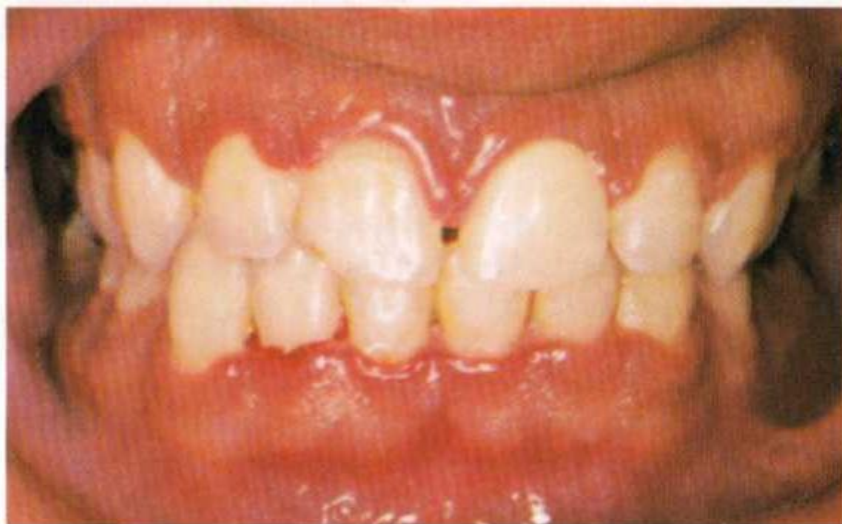
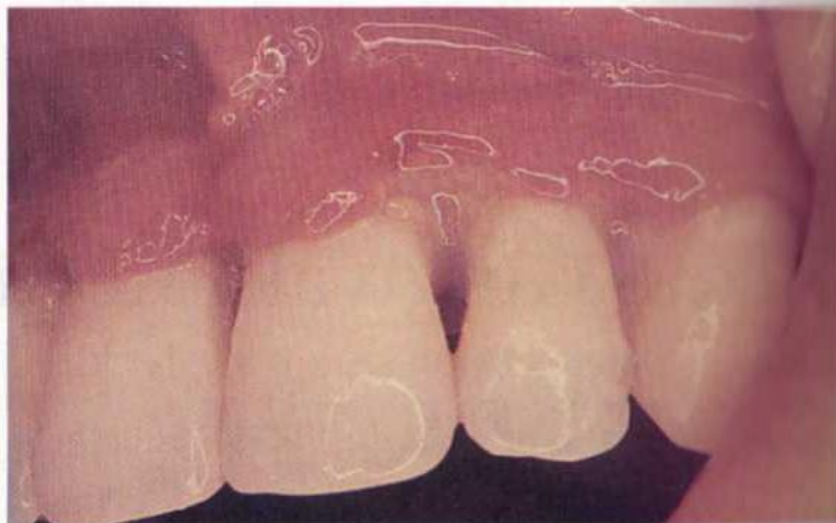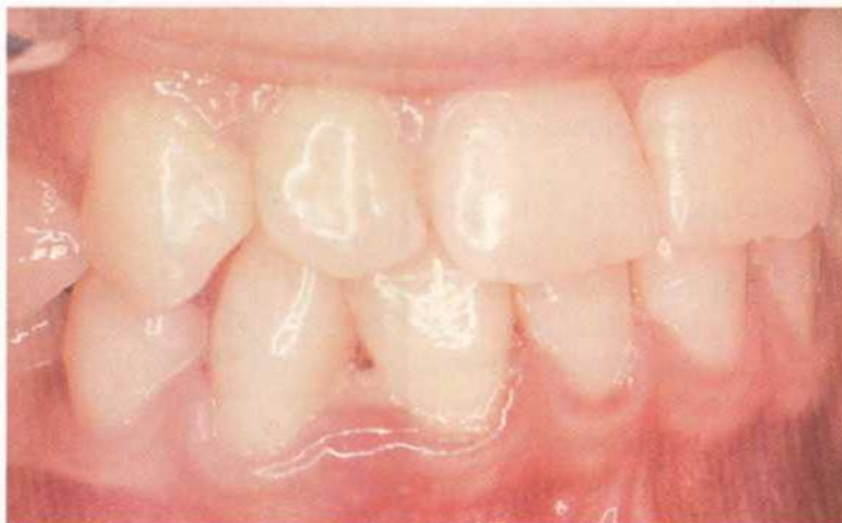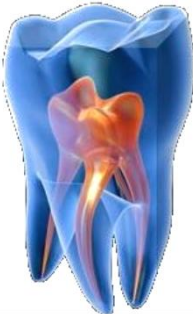Fig. Necrotizing ulcerative gingivitis



Oral signs. Characteristic lesion are punched out, craterlike depressions at the crest of the inter dental papillae:

- ❑ Subsequently extending to the marginal gingiva.
- ❑ Rarely to the attached gingiva and oral mucosa.
- ❑ The surface of the gingival craters is covered by a gray, pseudo membranous slough.
- ❑ Demarcated from the remainder of the gingival mucosa by a pronounced linear erythema.
- ❑ In same case the lesion are denuded of the surface pseudo membrane, exposing the gingival margin, which is red, shiny and hemorrhagic.
- ❑ The characteristic lesions may progressively destroy the gingiva and underlying periodontal tissues.
- ❑ Spontaneous gingival hemorrhage or pronounced bleeding after the slightest stimulation.
- ❑ Other sign often found are fetid odor and increased salivation.
- ❑ NUG can be super imposed on chronic gingivitis or periodontal pockets.

Oral symptoms.

- ❖ The lesions are extremely sensitive to touch.
- ❖ Patient often complains of constant radiating, growing pain that is intensified by eating spicy or hot foods and chewing.
- ❖ There is a “metallic” foul taste.
- ❖ Patient is conscious of an excessive amount of “pasty” saliva.



Extra oral and systemic signs and Symptoms.

- ❑ Patients are usually ambulatory and have a minimum of systemic symptoms.
- ❑ Local lymphadenopathy.
- ❑ Slight elevation in temperature (in the mild and moderate stages of the disease).
- ❑ In severe cases, there may be high fever:
 - Increased pulse rate.
 - Leukocytosis.
 - Loss of appetite.
 - General lassitude.
 - Systemic reactions are more severe in children.
 - Insomnia.
 - Constipation.
 - Gastro-intestinal disorders.
 - Headache.
 - Mental depression.
 - In very rare cases, severe sequelae such as gangrenous stomatitis.

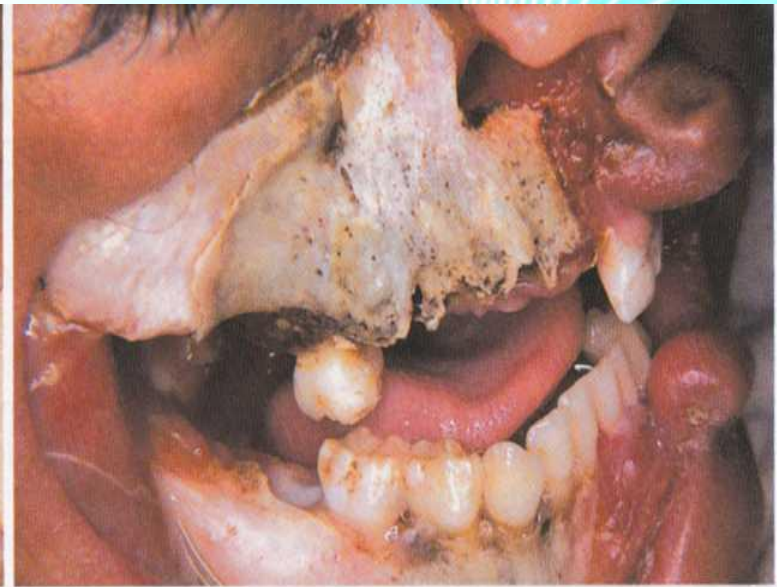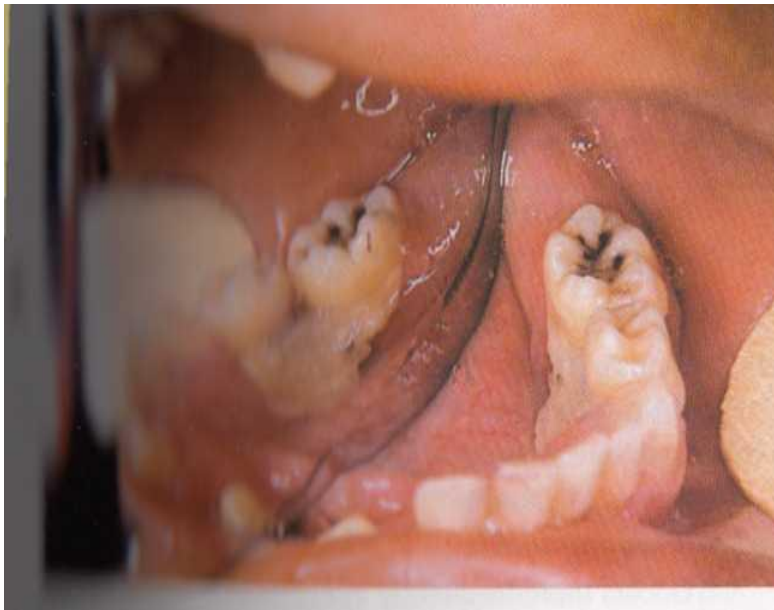


Fig. Severe cases of necrotizing gingivitis

Histopathology. Microscopically, the NUG lesion is acute necrotizing inflammation of the gingival margin, involving both the stratified squamous epithelium and the underlying connective tissue. The surface epithelium is destroyed and replaced by meshwork of fibrin, necrotic epithelial cells, polymorphonuclear leukocytes, and various types of microorganisms.

This is the zone appears clinically as the surface pseudo membrane. At the immediate border of the necrotic pseudo membrane, the epithelium is edematous.

The underlying connective tissue is extremely hyperemic, with numerous engorged capillaries. Numerous plasma cells may appear in the periphery of the infiltrate.



Relation of Bacteria to Characteristic Lesion

Light microscopy shows that the exudates on the surface of necrotic lesion contains microorganisms that morphologically resemble cocci fusiform bacilli and spirochetes.

The layer between the necrotic the living tissue contains enormous numbers of fusiform bacilli and spirochetes, in addition to leukocytes and fibrin.

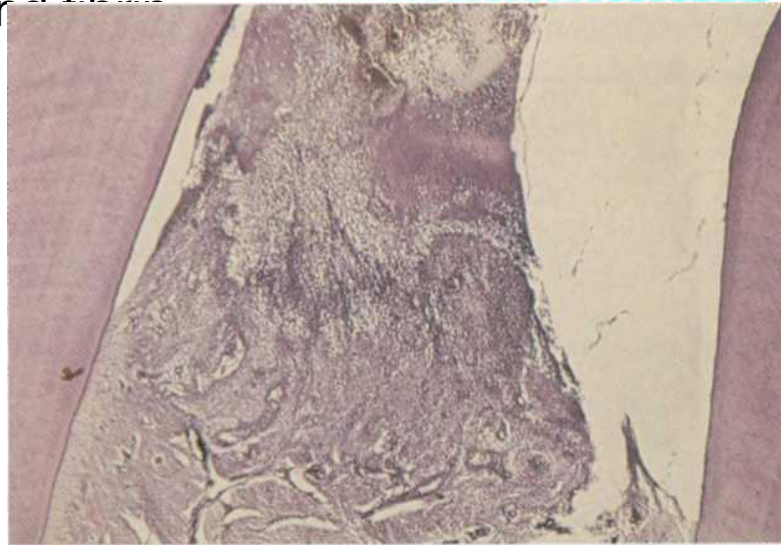


Fig. Survey section of inter dental papilla in necrotizing ulcerative gingivitis. Top portion of the section shows the necrotic tissue that forms the gray marginal pseudo membrane. In lower portion, note the ulceration and accumulation of leukocytes and fibrin.



Diagnosis

Diagnosis is based on clinical findings of gingival pain, ulceration, and bleeding. It can be used to differentiate NUG from specific infection as:

Tuberculosis.

Neoplastic disease.

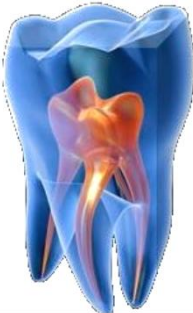Or nonspecific origin:

Trauma.

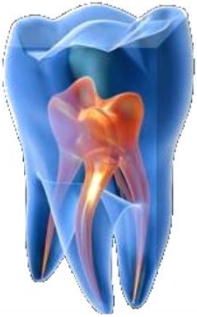Caustic medications.

NUG should be differentiated from us:

- ✓ Herpetic gingivostomatitis.
- ✓ Chronic periodontitis.
- ✓ Desquamative gingivitis.
- ✓ Streptococcal gingivostomatitis.
- ✓ Aphthous stomatitis.
- ✓ Gonococcal gingivostomatitis.
- ✓ Diphtheritic and syphilitic lesions.
- ✓ Tuberculous gingival lesions.
- ✓ Candidiasis.
- ✓ Agranulocytosis.
- ✓ Dermatoses (pemphigus, erythema multiforme, lichen planus).



Necrotizing Ulcerative Gingivitis	Primary Herpetic gingivostomatitis
<p>Etiology:</p> <ul style="list-style-type: none"> ▪ Interaction between hos and bacteria, most probably fusosperochetes. ▪ Necrotizing condition pinched-out gingival margin. ▪ Pseudomembrane that peels off leaving row areas. ▪ Marginal gingiva affected other oral tissues rarely affected. ▪ Uncommon in children. ▪ No defined duration. ▪ No demonstrated immunity. ▪ Contagion not demonstrated. 	<p>Etiology:</p> <ul style="list-style-type: none"> ▪ Specific viral etiology. ▪ Diffuse erythema and vesicular eruption. ▪ Vesicle rapture and leave slightly depressed oval or spherical ulcer. ▪ Diffuse involvement of gingiva; May include bucal mucosa and lips. ▪ Occurs more frequently in children. ▪ Duration of 7 up to 10 days. ▪ Acute episode result in some degree of immunity. ▪ Contagion.



Necrotizing Ulcerative Gingivitis

Bacterial smears show fuzospirochetal complex.

Marginal gingival affected.

Acute history.

Painful.

Pseudo membrane.

Pupillary and marginal necrotic lesions.

Affects adult of both genders, occasionally children.

Characteristic fetid odor

Desquamative Gingivitis

Bacterial smears reveal numerous epithelial cells, few bacterial forms.

Diffuse involvement of marginal and attached gingivae and other areas of oral mucosa.

Chronic history

May or may not be painful

Patchy desquamation of gingival epithelium

Papillae do not undergo necrosis.

Affects adults, most often women

None

Chronic Destructive Periodontal Disease

Bacterial smears are variable.

Marginal gingiva affected

Chronic history

Painless if uncomplicated

Generally no desquamation, but purulent material may appear from pockets.

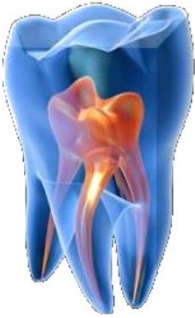Papillae do not undergo noticeable necrosis.

Generally in adults, occasionally in children

Some odor present but not strikingly fetid



Necrotizing Ulcerative Gingivitis	Diphtheria	Secondary Stage of Syphilis (Mucous Patch)
Etiology:	Specific bacterial etiology:	Specific bacterial etiology:
Interaction between host and bacteria, most probably fusospirochetes.	<i>Corynebacterium diphtheriae</i>	<i>Treponema pallidum</i>
Affects marginal gingiva	Rarely affects marginal gingiva	Rarely affects marginal gingiva
Membrane removal easy	Membrane removal difficult	Membrane not detachable
Painful condition	Less painful	Minimal pain
Marginal gingiva affected	Throat, fauces, and tonsils affected	Any part of mouth affected
Serologic findings normal	Serologic findings normal	Serologic findings abnormal
Immunity not conferred	Immunity conferred by an attack	Immunity not conferred
Doubtfully contagiousness	Contagion	Only direct contact will communicate disease.
Antibiotic therapy relives simptoms	Antibiotic treatment has minimal effect.	Antibiotic therapy has excellent results.



Etiology.

Role of bacteria. Plaut (1894) and Vincent (1896) introduce the concept that NUG is caused by specific bacteria: fusiform bacillus and spirochete organisms.

Local Predisposing Factors.

- Preexisting gingivitis;
- Injury to the gingiva;
- Smoking (important predisposing factor);
- Chronic gingival disease;
- Periodontal pockets (deep);
- Pericoronal flaps.

Systemic Predisposing Factors.

- Fully functional immune system (immune deficiency).
- Nutrition deficiency.
- Sleep deficiency.
- Abuse of alcohol, drug.
- Systemic disease (diabetes, debilitating).
- Psychosomatic factors (into the armed forces, school examinations).



DESQUAMATIVE GINGIVITIS

First reported was in 1894, but the term “Chronic desquamative gingivitis” (DG) was coined in 1932 by Prinz, to describe by intense erythema, desquamation, and ulceration of the free and attached gingiva.

Patients may be asymptomatic; when symptomation can have a mild burning sensation to an intense pain. 50% of desquamative gingivitis cases are localized to the gingiva. DG may occur as early as puberty or as late as the seventh or eighth decade, a hormonal derangement was suspected.

Approximately 75% of DG cases have a dermatologic genesis. Cicatricial pemphigoid and lichen planus account for more than 95% of dermatologic cases.

However, many other mucocutaneous autoimmune condition such as bullous pemphigoid, pemphigus vulgaris, dermatitis herpetiformis, lupus erythematosus and chronic ulcerative stomatitis can clinically manifest as desquamative gingivitis.

Biopsy.

Given the extent and number of lesions that may be present in a given individual, an incisional biopsy, and alternative to begin the microscopic and immunologic evaluation. Important is selection of the biopsy site – avoid areas of ulceration because necrosis and epithelial denudation severely hamper the diagnostic process

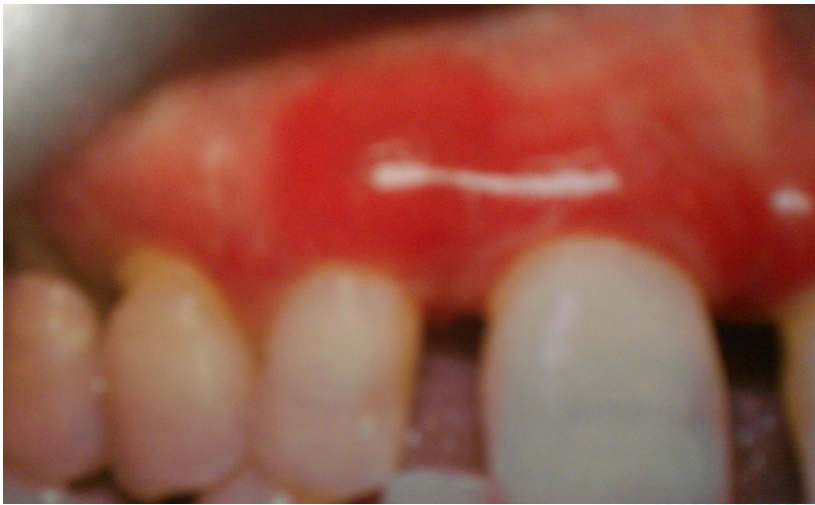

Fig. Chronic desquamative gingivitis (erythema)

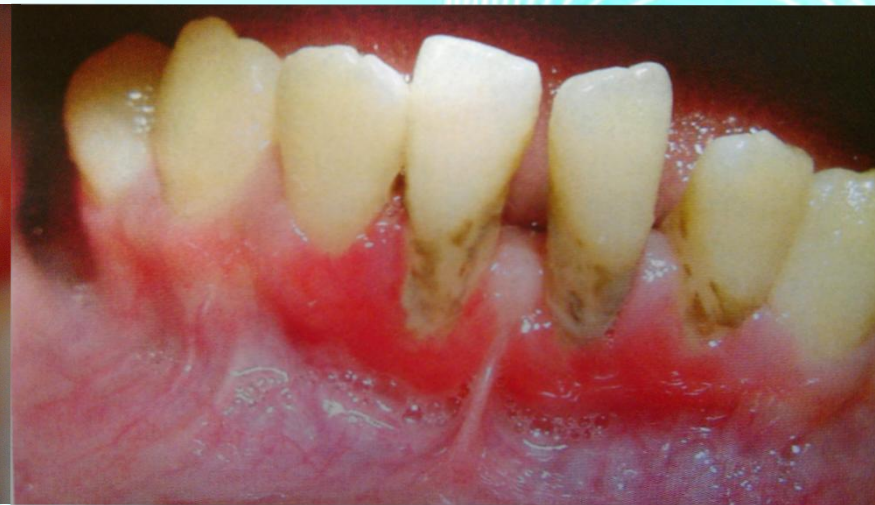

Fig. Desquamative gingivitis (Erithematous ulcerated and painful)

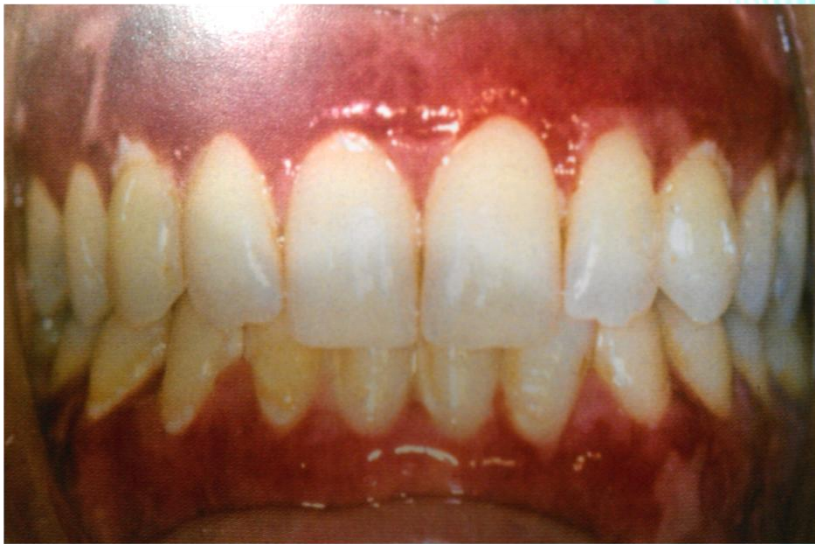

Fig. Typical desquamative gingivitis

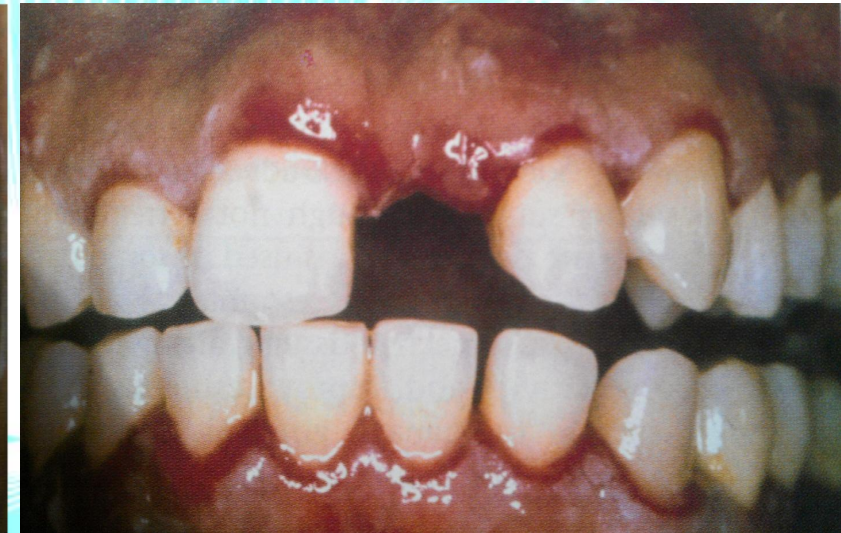

Fig. Desquamative gingivitis

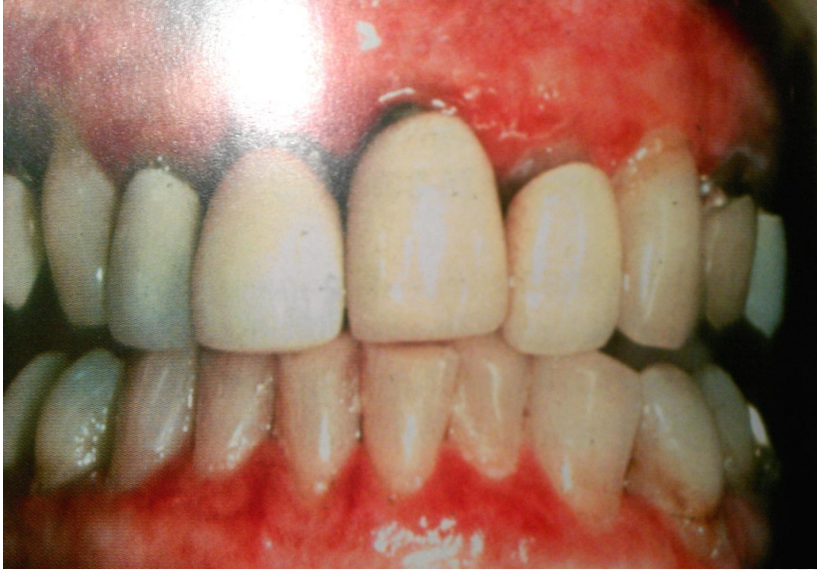


Fig. Chronic ulcerative stomatitis

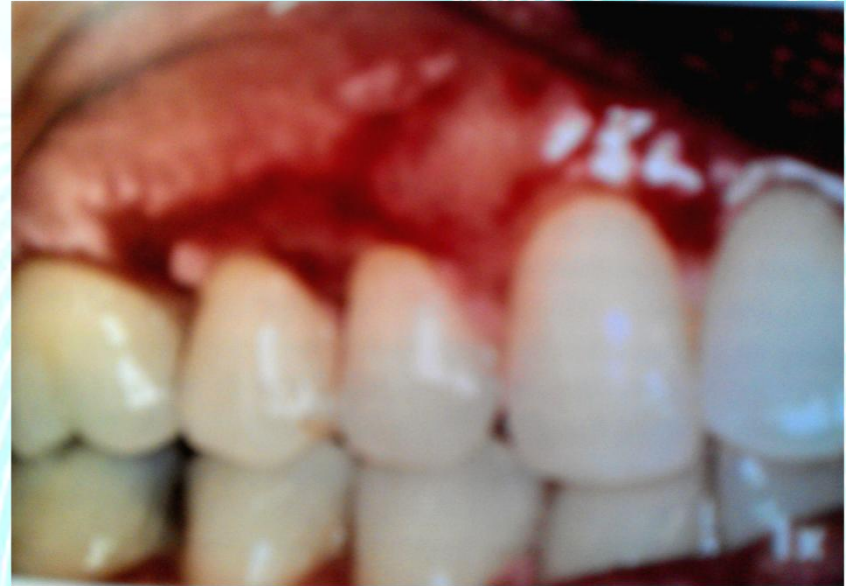

Fig. Lupus erythematosus
(Desquamative gingivitis)

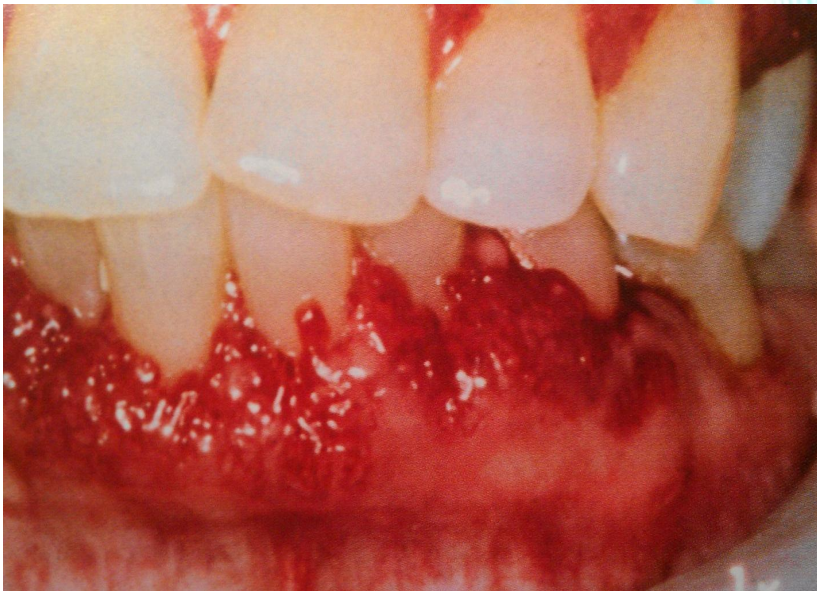

Fig. Wegener's granulomatosis
classic "Strawberry gums".
Desquamative gingivitis.



CATARAL GINGIVITIS

The prevalence of gingivitis is evident worldwide.

For example, epidemiologic studies indicate that more than 82% of US adolescents have overt gingivitis and signs of gingival bleeding.

A similar of higher prevalence of gingivitis is reported for children and adolescents in other part of the world.

In general, clinical features of gingivitis may be characterized by the presence of any of the following clinical signs:

- ☐ Redness;
- ☐ Sponginess of the gingival tissue;
- ☐ Bleeding on provocation;
- ☐ Changes in contour;
- ☐ Presents of calculus or plaque;
- ☐ With no radiographic evidence of crestal bone loss.

Gingivitis can occur with sudden onset and short duration on can be painful.

Recurrent gingivitis reappears after having been eliminated by treatment or disappearing spontaneously.

Chronic gingivitis is slow in onset and of long duration. It is painless, unless complicated by acute or sub acute exacerbations. Chronic gingivitis is a fluctuating disease in which inflammation persists or resolves and normal areas become inflamed.



Localized gingivitis is confined to the gingiva of a single tooth, or group of teeth.

Generalized gingivitis involves the entire mouth.

Marginal gingivitis involves the gingival margin and may include a portion of the attached gingiva.

Papillary gingivitis involves the interdental papillae and often extend into the adjacent portion of the gingival margin. Papillae are involved more frequently than the gingival margin.

Diffuse gingivitis – affects the gingival margin the attached gingiva and the interdental papillae.

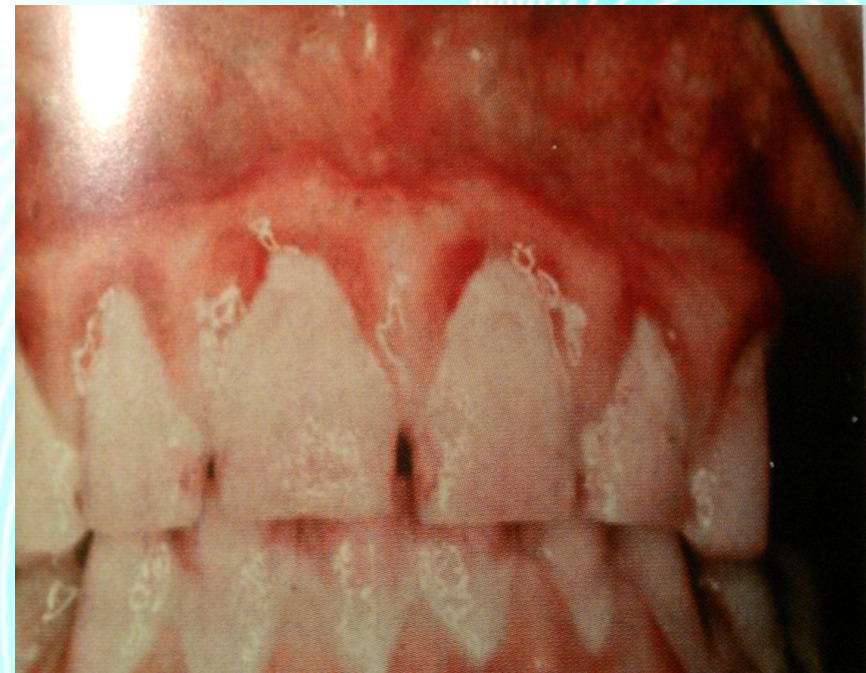

Fig. Chronic inflammatory gingival enlargement (smooth, edematous, discolored)

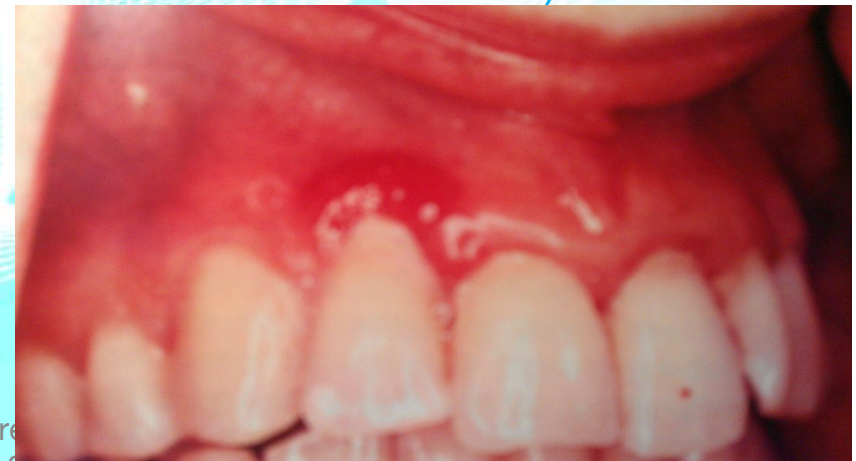

Fig. Localized, diffuse, intensely red area, dark-pink marginal changes

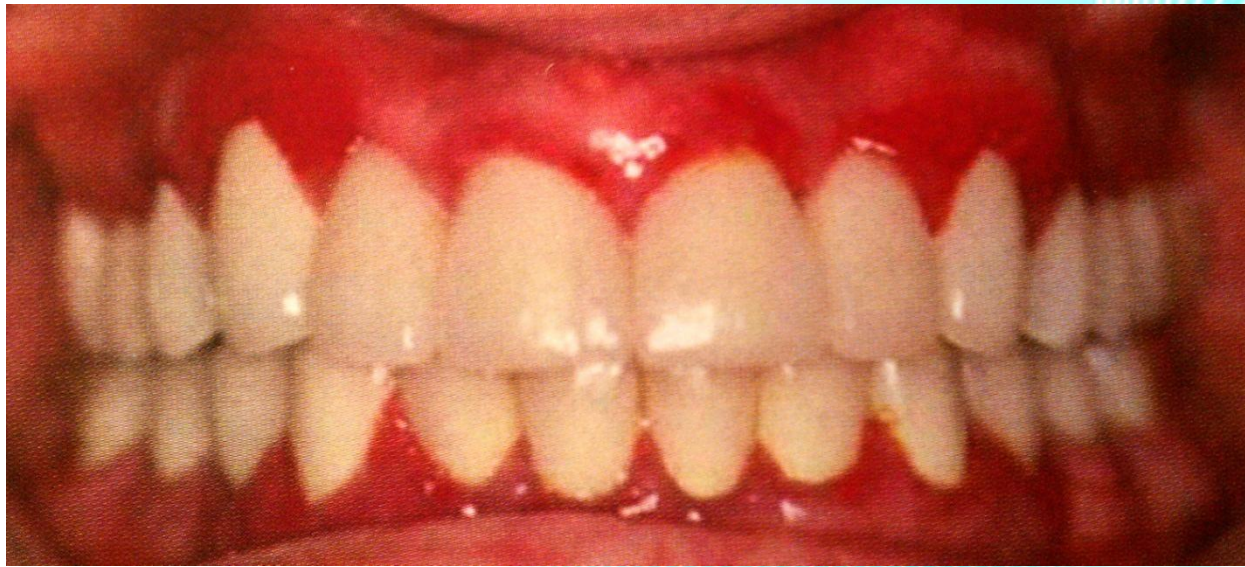

Fig. Generalized marginal gingivitis

Clinical findings

An orderly examination of the gingiva for:

Color.

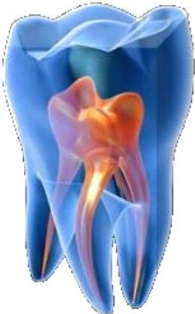Contour.

Consistency.

Position.

Bleeding (easy, severity).

Pain (easy, severity).



Gingival bleeding varies in severity, duration, and ease of provocation. Bleeding on probing is easily detected clinically is of value for the early diagnosis. Bleeding on probing appears earlier than a change in color.

Gingival bleeding caused by local factors, contributing factors to plaque retention include:

- ☐Anatomic and developmental tooth variations ;
- ☐Caries;
- ☐Frenum pull;
- ☐Iatrogenic factors;
- ☐Malpositioned teeth;
- ☐Mouth breathing;
- ☐Overhangs;
- ☐Partial dentures;
- ☐Lack of attached gingiva;
- ☐Recession.

The bleeding is chronic or recurrent and is provoked by mechanical trauma (from tooth brushing, tooth picks, or food impaction) or by biting into solid food, such as apples.

The severity of bleeding and the ease of its provocation depend of the intensity of the inflammation. Bleeding recurs when the area is irritated.



Acute episode of gingival bleeding are caused by injury and can occur spontaneously in gingival disease. Laceration of the gingiva by tooth brush bristles during aggressive tooth brushing or by sharp pieces of hard food can cause gingival bleeding.

The two earliest signs of gingival inflammation preceding established gingivitis are:

- ❖ Increased gingival crevicular fluid production rate.
- ❖ Bleeding from the gingival sulcus on gentle probing.

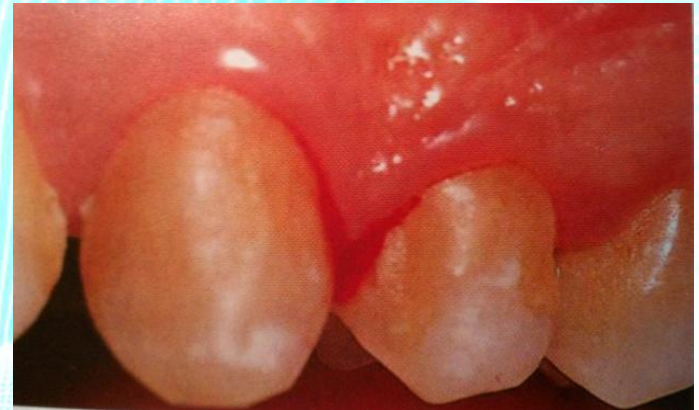
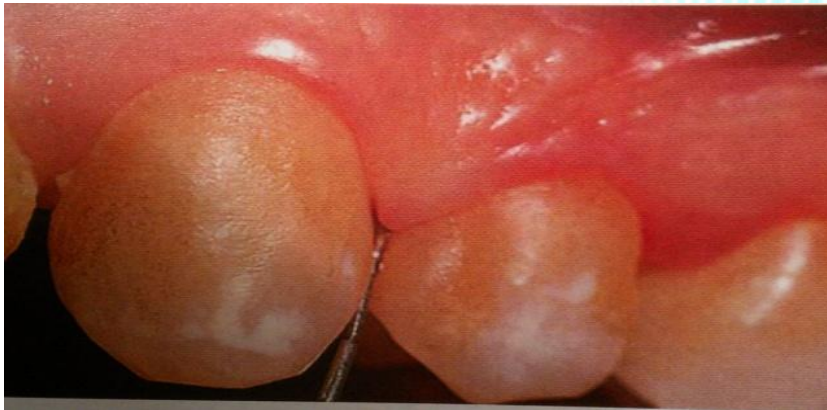
Fig. Bleeding on probing

Color changes in gingivitis. Changes is an important clinical sign of gingival disease. The normal gingival color is “Coral pink” and is produced by the tissue’s vascularity and modified by the overlying epithelial layer. The gingiva becomes red when vascularization increases or the degree of epithelial keratinization is reduced or disappears. The color becomes pale when

vascularization is reduced (in association with fibrosis) or epithelial ceratinization increases



Thus, chronic inflammation intensifies the red or blush red color because of vascular proliferation and reduction of keratinization.

Additionally, venous stasis will contribute a bluish hue. The gingival color changes with increasing chronicity of the inflammatory process. The changes start in interdental papillae and gingival margin and spread to the attached gingiva. In severe acute inflammation, the red color gradually becomes a dull, whitish gray. The gray discoloration produced by tissue necrosis is demarcated from the adjacent gingiva by a thin, sharply defined erythematous zone.

Changes in consistency of gingiva. Both chronic and acute inflammations produce changes in the normal form and resilient consistency of the gingiva. As in chronic gingivitis, both destructive (edematous) and reparative (fibrotic) changes coexist, and the consistency of the gingiva changes accordingly by their relative predominance.

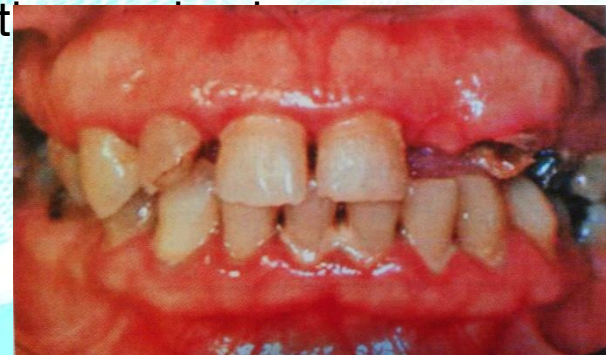
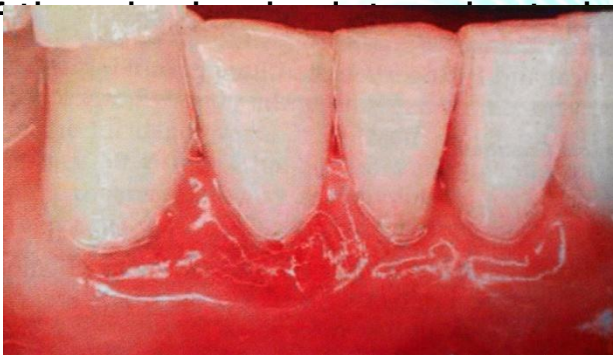
Fig. A - Chronic gingivitis, Gingiva is soft, friable and bleeds easily
B – Fibrosis predominates in the inflammatory process



Changes in position of the gingiva.

Gingival recession – (definition) is exposure of the root surface by an apical shift in the position of the gingiva.

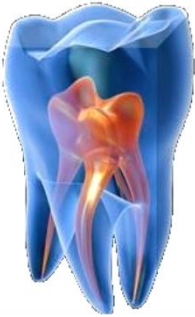Recession refers to the location of the gingiva, not its condition. Receded gingiva can be inflamed by may be normal except for it position.

Recession may be localized to one tooth or a group of teeth, or it may be generalized.

HIPERPLASTIC GINGIVIT (GINGIVAL ENLARGMENT)

Hypertrophic gingivitis. In the clinic in hypertrophic gingivitis is predominate proliferative processes. Hypertrophic gingivitis has an acute course, however, identified two forms - swollen and fibrous.

Edematous form is more common. Hypertrophy of the gums is usually preceded by serous, catarrhal inflammation. In the oral cavity can be observed simultaneously and catarrhal and hypertrophic changes.



Proliferation gums cause the following factors:

- ☐ Overhanging edges of fillings,
- ☐ Anomalies of the teeth,
- ☐ A deep bite,
- ☐ Endocrine changes,
- ☐ Taking hydantoin for epilepsy,
- ☐ Poorly constructed bridges,
- ☐ Changes from white blood.
- ☐ Hypovitaminosis C,
- ☐ Tartar.

Patients' complaints:

- ☐ overgrowth of gum
- ☐ bleeding when brushing your teeth,
- ☐ peel the gum from the teeth,
- ☐ Pain in the gums when eating.

Edematous form:

- ☐ gingival papillae increased in size, round,
- ☐ bluish color with a shiny smooth surface,
- ☐ bleeding upon probing.



The fibrous form is characterized by:

- hyperplasia;
- seal papillae;
- color - pale;
- no bleeding;
- surface is uneven, hilly;
- false notes in probing pocket.

There are three degrees of hypertrophic gingivitis.

Grade 1 - hypertrophy of the gingival papillae on the third crown of the tooth;

Grade 2 - half of the tooth crown;

Grade 3 - more than half of the crown and can reach up to incisal and occlusal tooth surfaces.



Clinical features – chronic inflammatory enlargement (gipertrofical gingivitis).

Chronic inflammatory gingival enlargement originates as a slight ballooning of the interdental papilla and marginal gingiva. In the early stages it produces a life preserver – shaped bulge around the involved teeth. This bulge can increase in size until it cover part of the crowns. The enlargement may be localized or generalized and progresses slowly and painlessly. Clinically inflammatory gingival enlargement show the exudative and proliferative features of chronic inflammation.

Lesions that are clinically deep red or bluish red are soft and friable with a smooth, shiny surface, and they bleed easily. They else have a preponderance of inflammatory cells and fluid, with vascular engorgement, new capillary formation and associated degenerative changes.

fibroblast

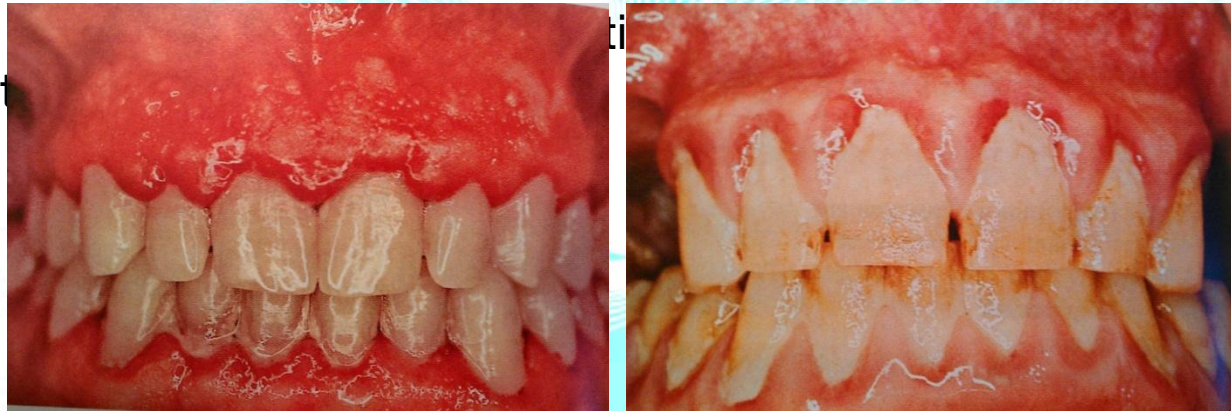


Fig. Chronic inflammatory gingival enlargement



Etiology caused by:

- ❖ Prolonged exposure to dental plaque;
- ❖ Poor oral hygiene;
- ❖ Irritation by anatomic abnormalities;
- ❖ Improper restorative;
- ❖ Orthodontic appliances;
- ❖ Drug induced gingival enlargement;
- ❖ Idiopathic gingival enlargement;
- ❖ Enlargement in vitamin C deficiency;
- ❖ Systemic diseases (leukemia);
- ❖ Hormonal conditions (pregnancy, puberty).

Anticonvulsants – the first drug induced gingival enlargements produced by phenitoin (dilantin) - is a hydantoin , introduced by Merritt and Putnam in 1938 for the treatment of all forms of epilepsy. Other hydantoins known to induce gingival enlargement are:

- ☐ Ethotoin (Paganone);
- ☐ Mephenytoin (Mesantoin);
- ☐ Succinimides (Zerontin);
- ☐ Methsuxinimide (Celontin);
- ☐ Valproic acid (Depakene).



Gingival enlargement occurs about 50% of patients receiving the drug, other authors have reported incidences from 3% to 84,5%.

Phenytoin may induce a decrease in collagen degradation as a result of the production of an inactive fibroblastic collagenase. The administration of the Phenytoin may precipitate a megaloblastic anemia and

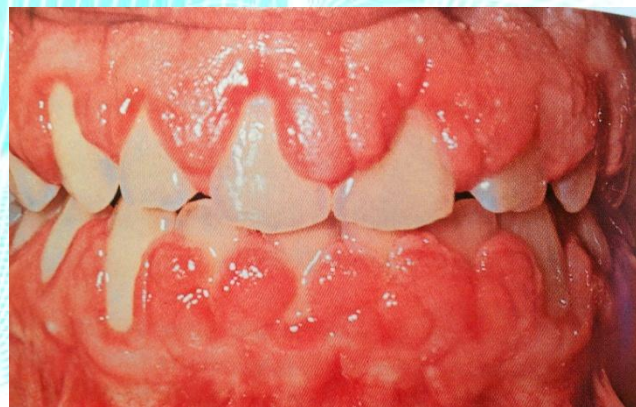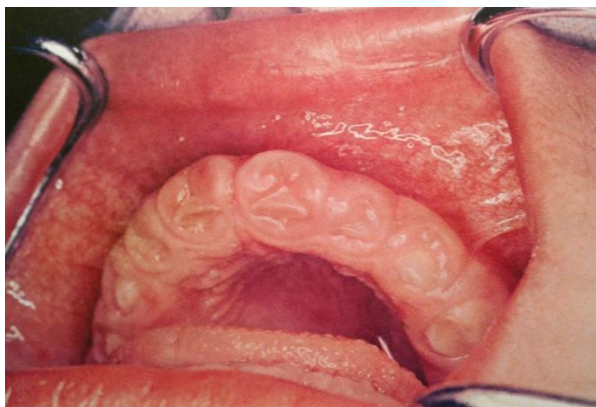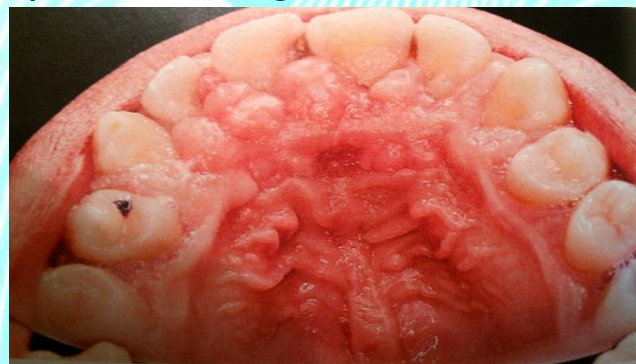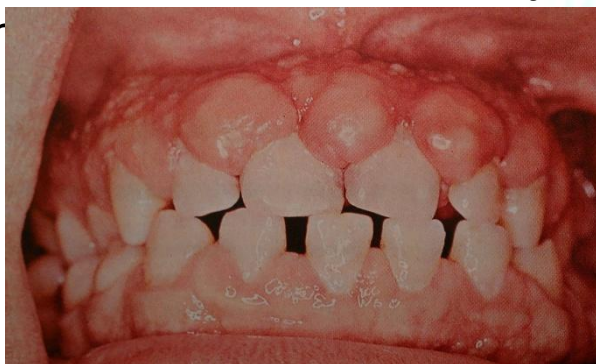


Fig. Gingival enlargement, associated with phenytoin therapy



ENLARGEMENT IN PREGNANCY

Pregnancy gingival enlargement may be:

- Marginal;
- Generalized.

During pregnancy there is an increase in levels of both progesterone and estrogen, which, by the end of the third trimester, reach levels 10 and 30 times the levels during the menstrual cycle, respectively.

This hormonal changes induce changes in vascular permeability, leading to gingival edema, and an increased inflammatory response to dental plaque (subgingival microbiota may also undergo changes).

Has been reported (PGS) as 10% and 70%.

The clinical picture.

- ❑ Various considerably;
- ❑ Enlargement is usually generalized;
- ❑ More prominent interproximally on the facial and lingual surface.
- ❑ Enlarged gingiva is bright red or magenta;
- ❑ Soft and friable;
- ❑ Has smooth, shiny surface;
- ❑ Bleeding occurs spontaneously;
- ❑ On slight provocation.

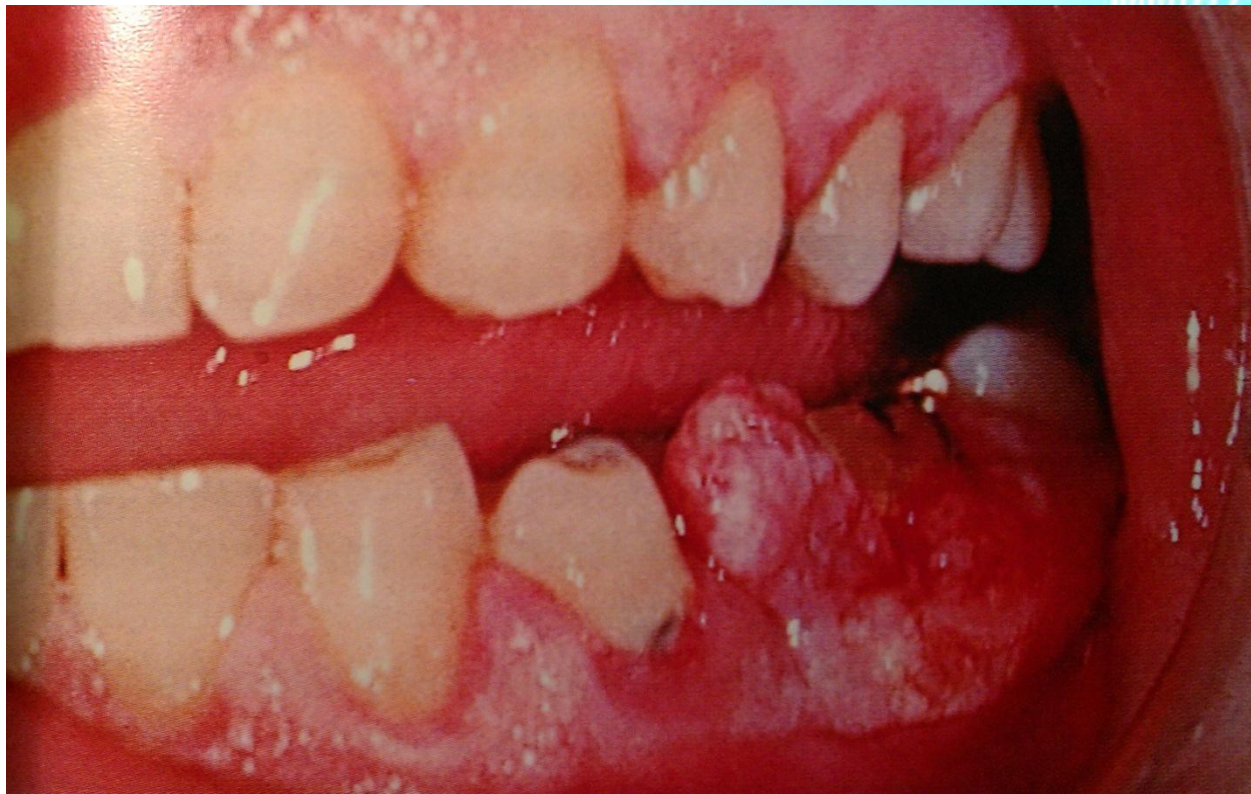

Fig. Localized gingival enlargement
(pregnant patient)



ENLARGEMENT IN PUBERTY

It occurs in both male and female adolescents and appears in areas of plaque accumulation.

The clinical picture:

- ❑ Association with local factors;
- ❑ Gingival enlargement is marginal and inter dental;
- ❑ Is characterized by prominent bulbous inter proximal papillae;
- ❑ Often, only the facial gingival are enlarged;
- ❑ Lingual surfaces are relatively unaltered;
- ❑ Have a clinical features generally associated with chronic inflammatory gingival diseases;
- ❑ After puberty the enlargement undergoes spontaneous reduction but does not disappear until plaque and calculus are removed.

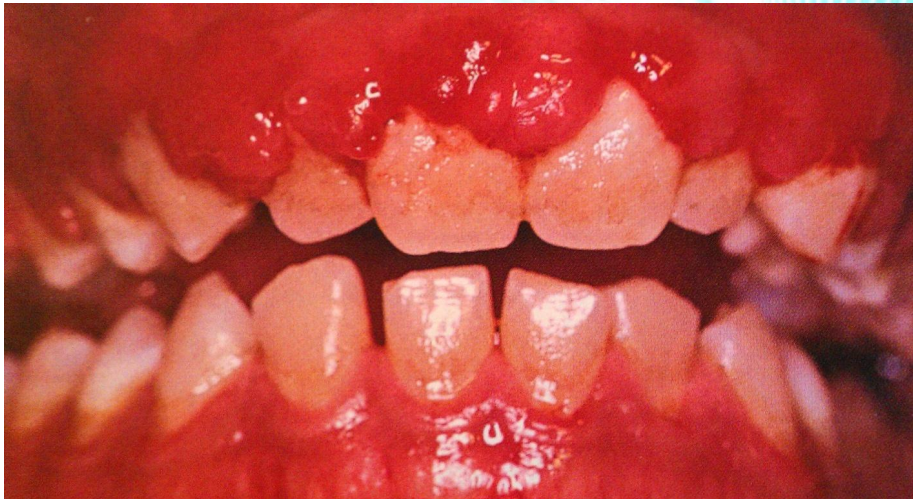

Fig. Gingival enlargement in puberty (13 year-old, boy)



ENLARGEMENT IN VITAMIN C DEFICIENCY

Acute vitamin C deficiency itself does not cause gingival inflammation.

It does cause:

- Hemorrhage;
- Collagen degeneration;
- Edema of gingival connective tissue.

Clinical picture:

- Gingival enlargement in vitamin C deficiency is marginal.
- The gingiva is bluish red.
- Soft and friable.
- Has a smooth, shiny surface.
- Hemorrhage – spontaneously or on slight provocation.
- Surface necrosis with pseudomembrane formation.

TREATMENT OF GINGIVITIS

In the treatment of acute aggravated catarrhal gingivitis use general therapy: fever, bracing, desensitization means. In the treatment of chronic catarrhal gingivitis prescribe vitamins C, P, A, B, E, and others.

Important in the treatment of catarrhal gingivitis is trained patient in the proper care of teeth, as it eliminates microbial plaque - the main causative factor of gingivitis. While studying conduct control of the individual hygiene of oral cavity by staining of the teeth with indicators (solution Schiller-Pisarev, Lugol, fuxin, etc.).



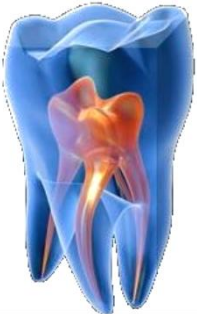Recommended for patients to brush their teeth three times daily after meals with a stiff brush, by synthetic bristle at least 3 min. Recommend that you change the brush every 1-2 months. Assign tooth paste of treatment and prevention group ("Forest», «Colgate Herbo», etc.).

For inactivation microbial plaque and facilitate its removal using 0.06% chlorhexidine 2-3 times a day for 2-3 minutes after brushing your teeth in a mouth trays for 5-7 days, as a relatively long using can lead to dysbacteriosis. Well-proven dental elixir "Ksident", based on ksifon containing bacterial additives and fluorine. Elixir diluted 1:1 with water and use as a rinse for mouth after brushing your teeth for 1 minute.

Widely used physical therapy treatment: electrophoresis of 5% solution of ascorbic acid, aminocaproic acid, calcium chloride solution, 1% solution galaskorbina at the gingival margin of the lower and upper jaws. In the course of treatment - 10-15 procedures, duration of treatment - 20 minutes.

Effective is massage the gingiva. On the course - 10 sessions, the duration of the procedure - 20 minutes.

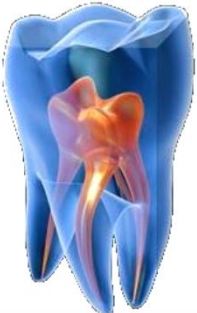Photophoresis butadion, indometacin unguent on gingival margin of both jaws (10 per treatment procedures, duration of treatment - 10 minutes) with acute catarrhal gingivitis, laser gingiva edge (on the course of 10 treatments, the duration of the procedure - 6-10 minutes).



Treatment of ulcerative gingivitis should be complex. Local treatment is aimed at eliminating inflammation of the mucous membrane, reduction of pain, removal of necrotic tissue, decrease toxicity and to create conditions unfavorable to the microflora activity, normalization of the exchange and stimulation of regenerative processes in the gingiva, prevention of recurrence of disease, stimulation of local immunity.

Orienting basis of the scheme for the treatment

The components of ulcerative gingivitis	Means of action	The criterion of self-control
Anesthetized gingiva: a) injectable form of anesthesia - infiltration, conduction anesthesia; b) Application anesthesia (topical).	2% solution of novocaine, 2 % Solution of lidocaine, 2% solution trimekaina, 1% solution of pyromekaina, and 4% p-p dikaina, 5% unguent piromekaina, 5% anestezin suspension.	Withdrawal symptoms of pain creates the conditions for all phases of treatment. After 15-20 minutes. proceed to treatment.
Perform antiseptic gingiva by rinsing the mouth trays, applying with cotton ball.	3% solution of hydrogen peroxide, 0.06% solution of chlorhexidine, 1% solution etoniya, 0.25% hlorfyllipta, 0.02% Frc (furacilini), 1% solution perpotassium permanganate.	Reducing the number of oral microbes. Appointment of a patient Rinse 3 times day of antiseptics after a meal.
Brush with tincture of iodine tincture gingival margin of the pathological focus	3% tincture of iodine.	Decontamination of the operative field.



Wear protective gloves and goggles (glass).	Protections goggles (glass). Rubber gloves.	Protected a doctor from the infection.
Remove necrotic deposits and dental plaque in the pathological focus in the following sequence: a) with the oral surface; b) the contact surface; c) to the vestibular surface.	Tool for professional hygiene, ultrasonic scaler.	
Spend a second antiseptic.		
Perform chemical purification of the gingiva from the necrotic plaque by applications, for 15-20 minutes.	Solutions of trypsin, chymotrypsin, himopsin, terrilitin, karipazim.	Spend the application sterile until cleaning of the gingiva necrotic deposits.
Spend application with antibacterial agent for 15-20 min.	Unguent: Iruksol, Dermazin, dioksikol, etoniy. Solutions: 0.25% hlorfilipt, Dioksidina 1%, 10% dimeksidina (patient on home), 1% etoniya, Salvini 0.25%, 1% Sanguirythrine.	applications every day to the complete purification necrotic deposits on the gingiva. Assign the application to the patient at home, 2-3 times a day for 15-20 min.
After 3-5-7 days after sloughing necrotic tissue (debrids)		
Spend appliqué keratoplastic drug for 15-20 min. Marginal gingiva edge of pathological focus.	Unguent: methyluracil, Actovegin, Solcoseryl, etoniya. Karo tolin, rosehip oil, chamomile oil, Sea Buckthorn Oil (Oblepiha), Vitamin A (oily solution) Vinylinum, olazol, gipozol.	spend application daily until complete healing of the gingiva. assign applications the patient at home, 2-3 times a day for 15-20 minutes.



Treatment of ulcerative gingivitis should be active from the first visit of patient. The success in treating this disease can only be achieved after the full removal of necrotic debris and dental deposit and calculus.

In the treatment of ulcerative gingivitis is necessary to consider the severity of the disease.

Under the local medication treatment of ulcerative gingivitis means the use of drugs applied to the pathological focus in different ways: in the form of irrigation, applications.

Medications used in the 1st phase of treatment of ulcerative gingivitis, should help to cleanse the wound suppress microflora and to create conditions for further healing. For this purpose, use proteolytic enzymes, antiseptics and chimico-therapeutic funds.

Drugs used in the 2nd phase of treatment of ulcerative gingivitis, should stimulate the repair processes. That's why during this period it is advisable to apply keratoplastics.

We recommend a rational oral hygiene with the use of tooth pastes that contain chlorophyll ("Forest", "Extra", "Softwood"), sea buckthorn oil ("Zodiac") and others.

Patients prescribed vitamins C and E, antihistamines, sulfonamides, antibiotics, nutrition, immune. Ulcerative gingivitis is widely used physiotherapy (laser therapy, UFO, UHF, etc.). Treatment of hypertrophic gingivitis necessary to carry out complex -common in conjunction with local, to the extent of hypertrophy, inflammation and the nature of the causal factors.

Common treatments include vitamin therapy, the treatment of systemic diseases, local medical, surgical, physiotherapy. Local treatment of chronic hypertrophic gingivitis is directed at removing dental deposit calculus, then the use of anti-inflammatory, anti-edemical, and as a last resort - sclerosing.



In hypertrophic pregnant gingivitis remove dental deposit (calculus), use control of oral hygiene, use of anti-inflammatory drugs and heparin. By surgical methods - gingivectomy start after giving birth. Conservative therapy is ineffective in this period. In the treatment of dilanti gingivitis should consult with a psychiatrist about the possibility of a temporary withdrawal of the drug and replacing it with another. Spend as professional hygiene give advice on oral hygiene, conductanti, anti-inflammatory therapy. Edema (granulating) form is converted into a fibrous form, produce Gingivectomy whan while maintaining hypertrophy.

In terms of treatment of hypertrophic gingivitis in anomaly of occlusions provide orthodontia therapy.

Of the medication in the treatment of fibrous forms of hypertrophic gingivitis use injection solution in the gingival papillae lidazy, 40% glucose, 0.25% solution of calcium chloride, 10% solution of calcium gluconate 0.1-0.2 mL, 3-8 procedures for the course with an interval of 1-2 days.

In the absence of the effect of sclerotization therapy have resorted to surgical excision of hypertrophied papillae.

Widely used physical therapy treatments. Electrophoresed 5% solution of potassium iodide, lidazy, ronidazy, heparin (14 sessions of 15-20 minutes). Also effective vacuum massage (6-10 treatments over 2-3 days), hydro massage (10 sessions of 20 minutes), darsonvalization of gingiva (10 sessions of 20 minutes). With the success and the use of



In the absence of the effect of conservative therapy, as well as the II-III degree of hypertrophy of the surgical treatment - gingivectomy, cryosurgery, diathermocoagulation.

The scheme of treatment of hypertrophic gingivitis

The components	Means of treatment	The criterion of self-control
Analgesia of gingiva: a) injectable form of anesthesia (infiltration, conduction anesthesia); b) Application (topical) anesthesia.	2% solution of novocaine, 2% solution lidocaine, 2% solution trimekaina, 1% solution piromekaina, anesthetics chloride, 10% lidocaine 4% solution dikaina, 5% ointment piromekaina, 1% solution piromekaina.	Withdrawal symptoms of pain will allow for all stages of treatment.
Perform antiseptic oral by mouth rinses, mouth trays, irrigation, applied cotton ball with a 3% tincture of iodine.	3% hydrogen peroxide solution, 0.06% chlorhexidine, 1% solution etoniya, 0, 2% solution hlorafillipta, 0.02% solution Frc, 1% solution of potassium permanganate.	Reducing the number of oral microbiota.
Wear goggles (glasses) and gloves.	Protection goggles (glasses) and rubber gloves.	Protected a doctor from the infection (contamination).
Remove dental deposits calculus.	Tool for professional hygiene, ultrastom (Schaller) .	



Spend a second antiseptic treatment of the gingiva.	Unguent: dioksikol, Dimexid, etoniy. Solutions: 0.5% hlorofillipta, 1% dioksidina, 10% dimeksidina (the patient at home), 1% etoniya, 0.25% Salvini, 1% Sanguirythrine.	Perform daily application to the disappearance of inflammation, that is, when Schiller-Pisarev probe will be negative.
Spend applique anti-inflammatory funds during the 15 - 20 min;		
Spend a keratolytic therapy in the form of applications on the gingiva for 15-20 minutes.	Maraslavin, poliminerola solution, the solution Befungin, lidazy solution, a solution of tincture of fungus, the solution vagotila, the juice of plantain, oil-alcohol suspension of propolis tincture and celandine (CHISTOTEL).	Spend application for as long as the papilla does not become normal in size.
Spend the sclerosing therapy by injection of 0.1-0.2 ml drug in the gingival hypertrophic (I-III) papillae.	40% solution of glucose, 0.25% solution of calcium chloride solution lidazy, ronidazy solution.	Spend 3 to 8 treatments.
Perform physiotherapy.	Electrophoresis 8% solution of potassium iodide, heparin, lidazy. Darsonvalization. Vacuum massage.	
Perform a partial gingivectomy in places persistent hypertrophy.	Scalpel, gingiva scissors.	Assign a home mouth wash with solutions of vagotila, poliminerola, Befungin, celandine tincture, propolis - 3 times.



The End